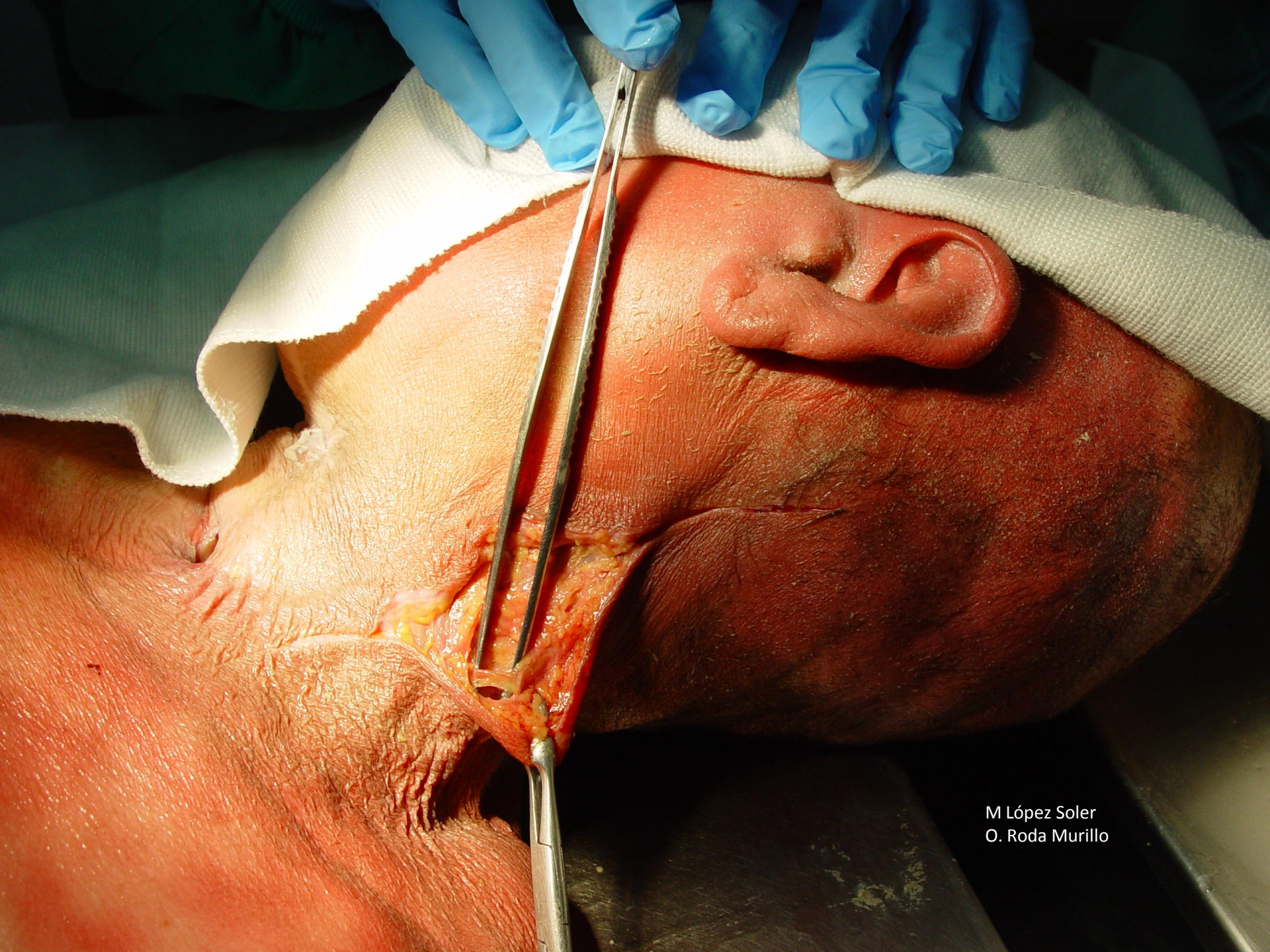

# PLEXO CERVICAL Y BRAQUIAL

Disecciones

M. López Soler  
O. Roda Murillo

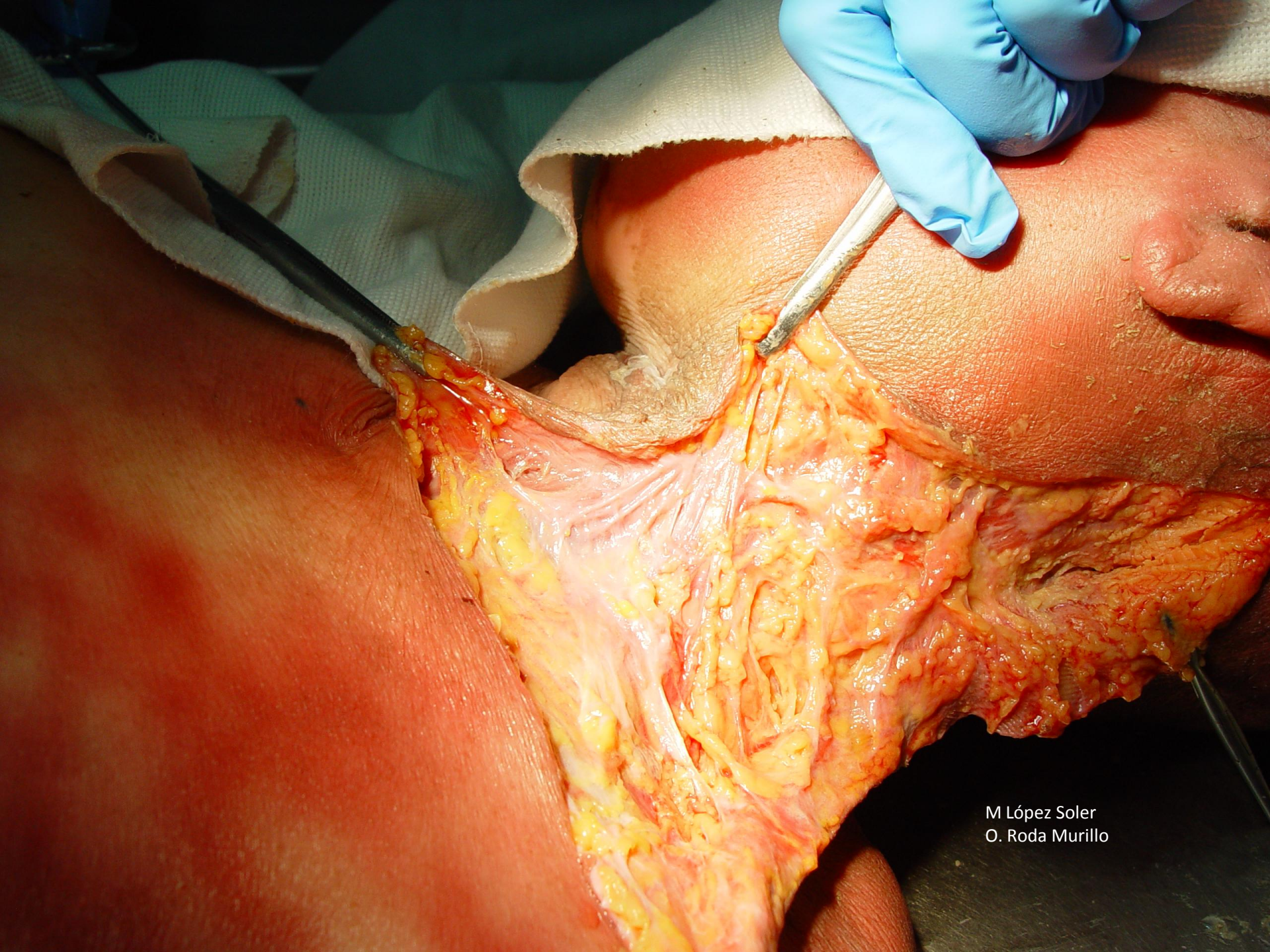


M López Soler  
O. Roda Murillo

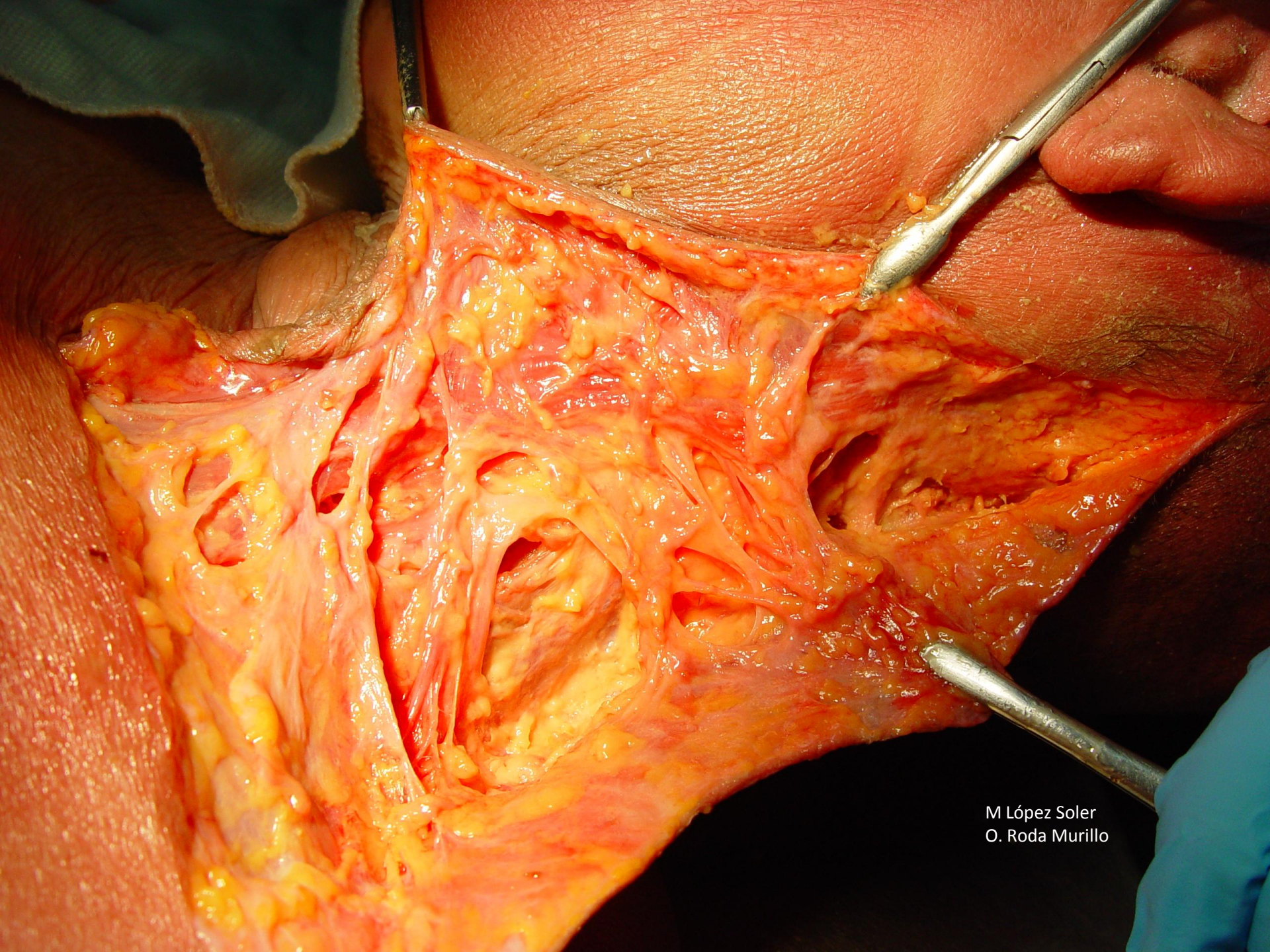
A surgical photograph showing a dissection of the supraclavicular region. The patient's head is tilted back, and the skin is retracted. A green curved line highlights a bundle of cutaneous nerves. Surgical instruments are visible, and the area is illuminated. The patient's ear and part of the face are visible on the right side of the image.

**NERVIOS  
SUPRACLAVICULARES  
(Cutáneos)**

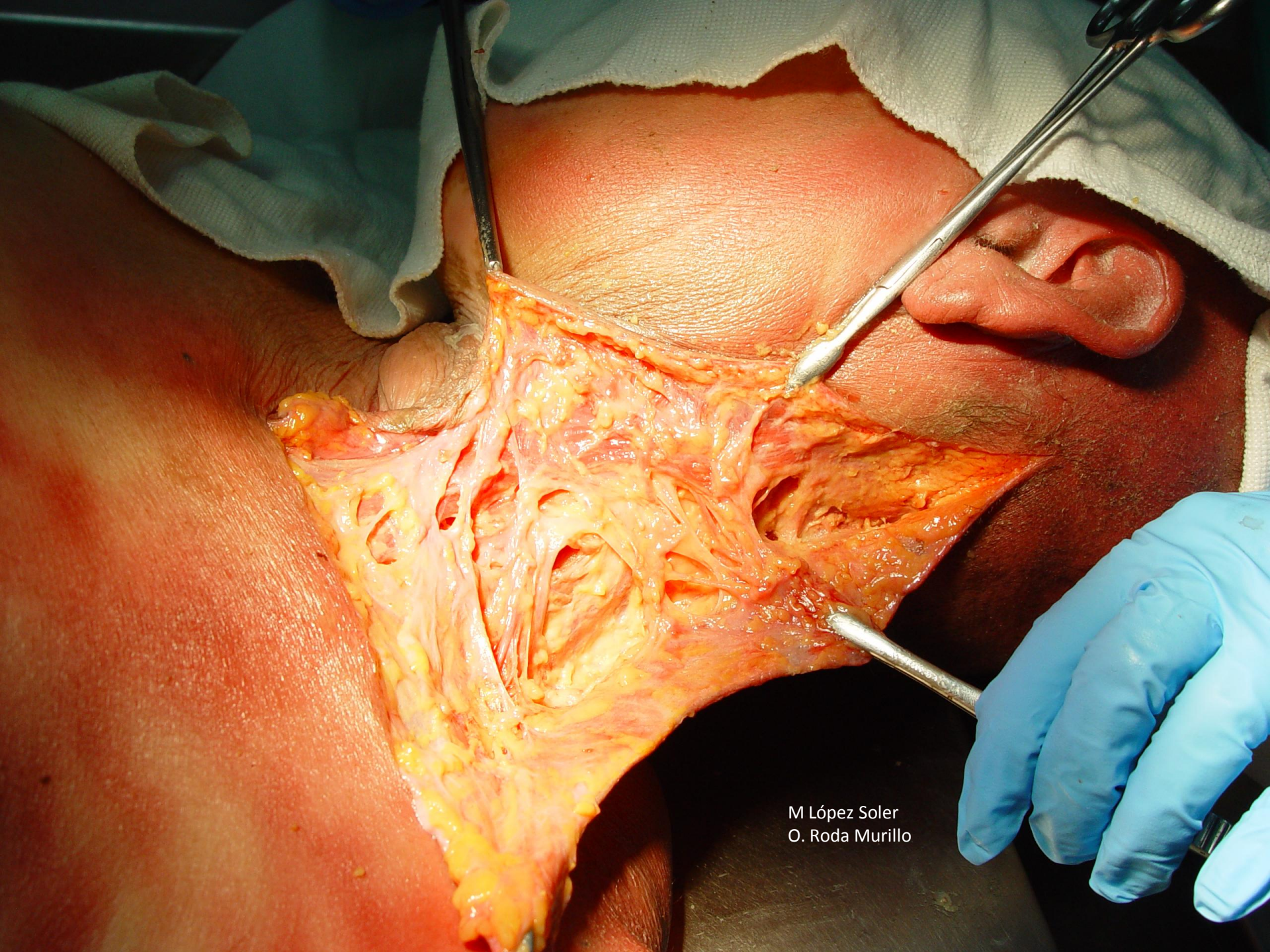
M López Soler  
O. Roda Murillo



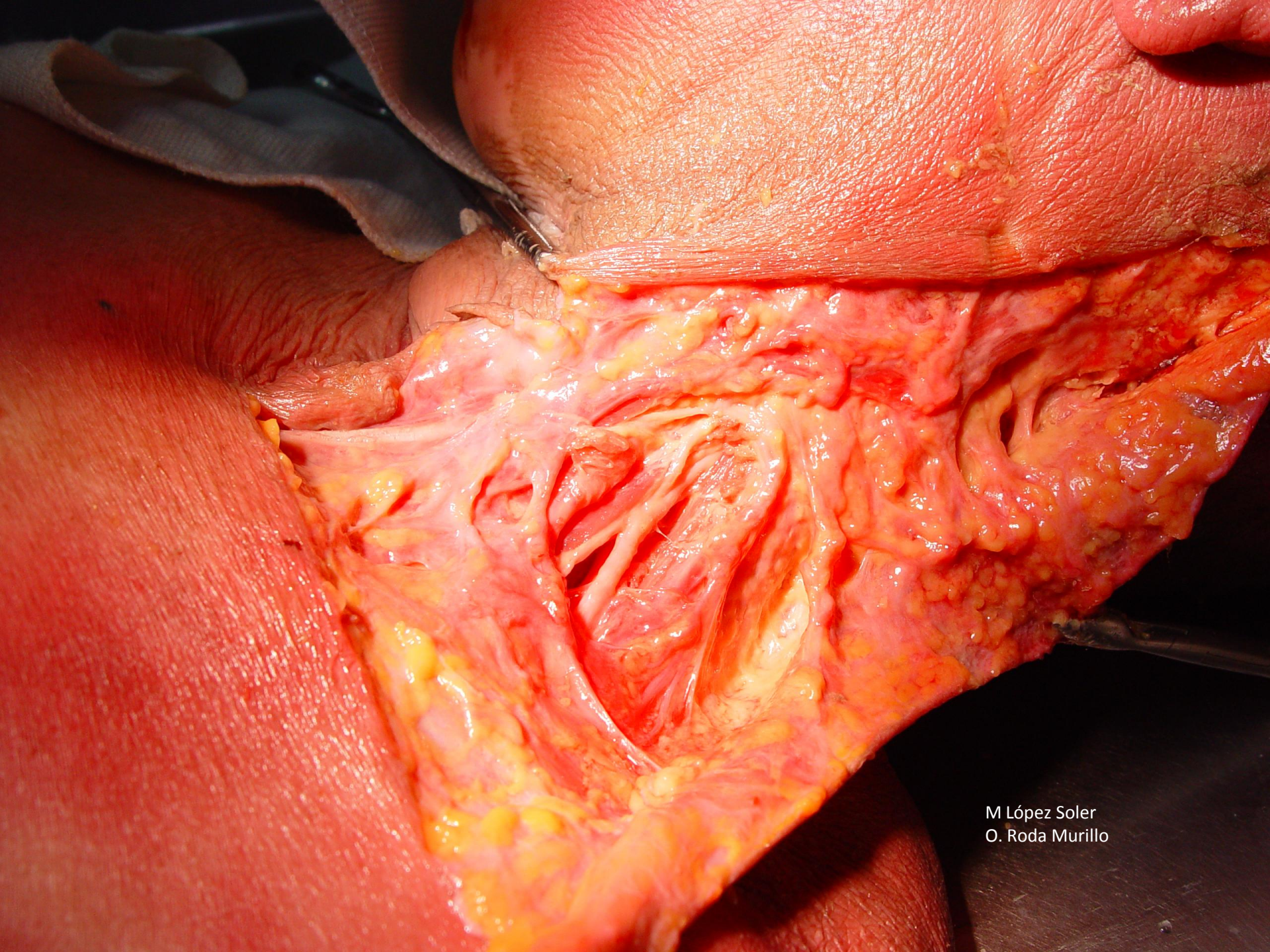
M López Soler  
O. Roda Murillo



M López Soler  
O. Roda Murillo

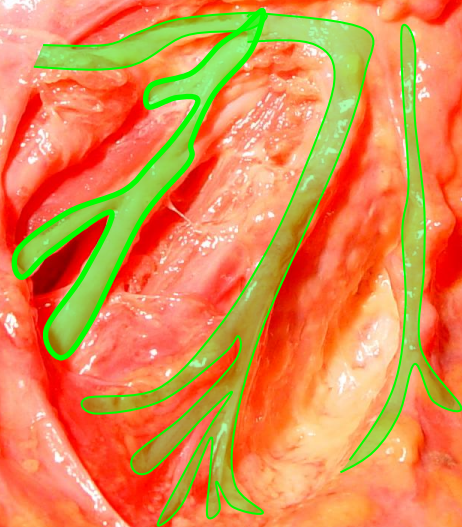

M López Soler  
O. Roda Murillo



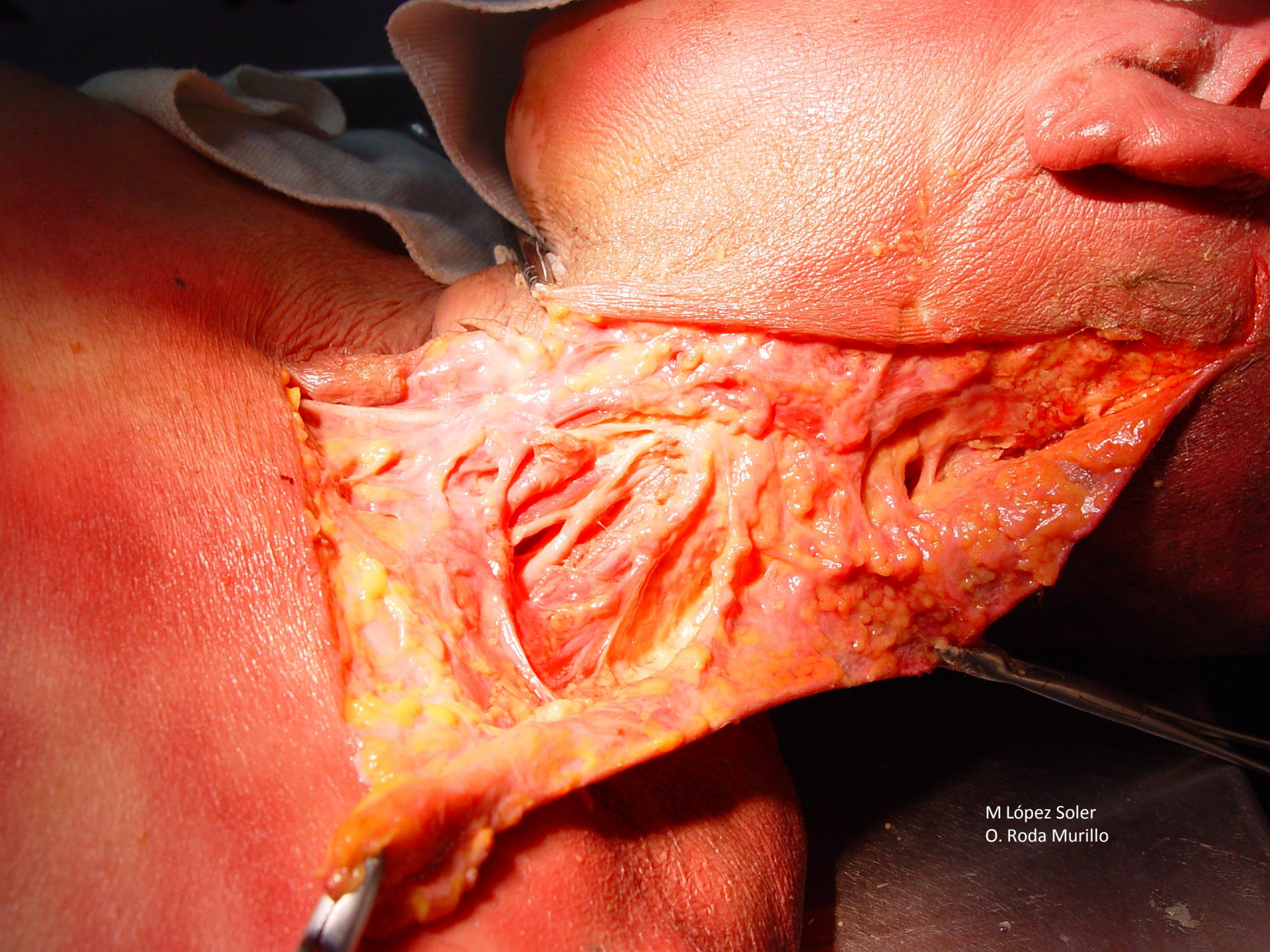
M López Soler  
O. Roda Murillo

**NERVIOS  
SUPRACLAVICULARES  
(Cutáneos)**



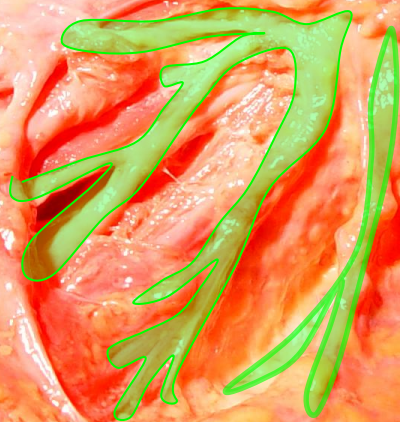M López Soler  
O. Roda Murillo



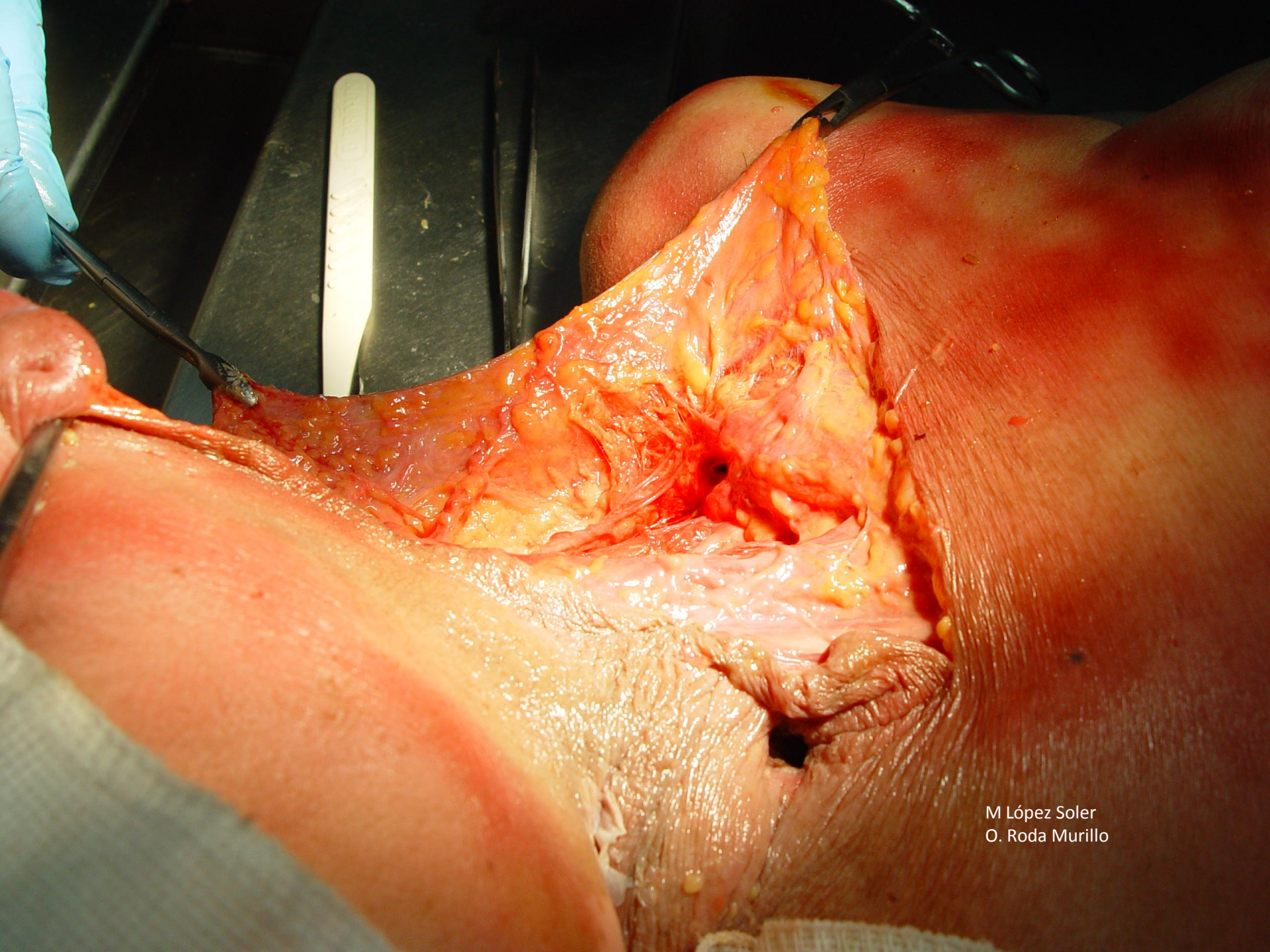


M López Soler  
O. Roda Murillo

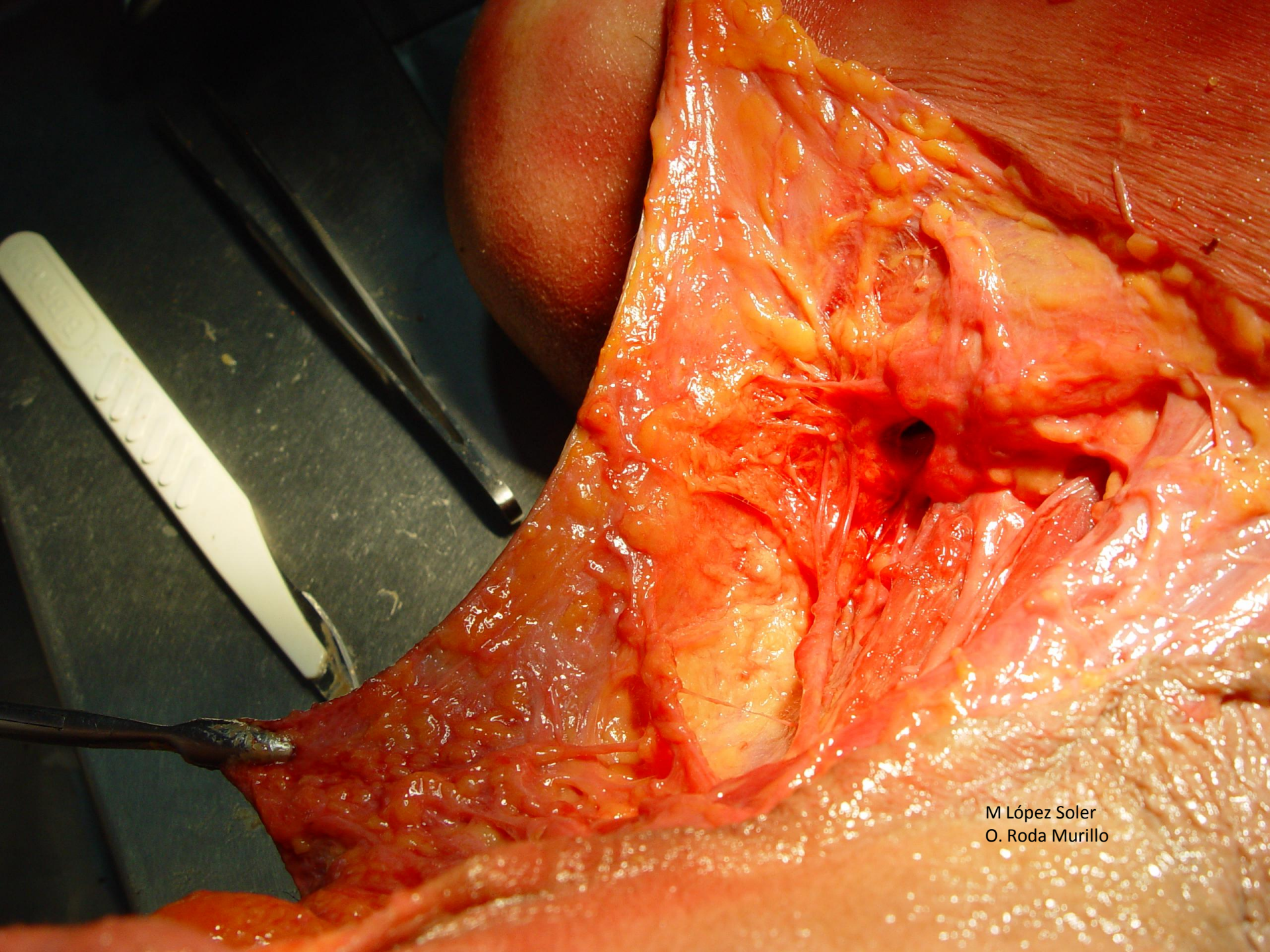
**NERVIOS  
SUPRACLAVICULARES  
(Cutáneos)**



M López Soler  
O. Roda Murillo

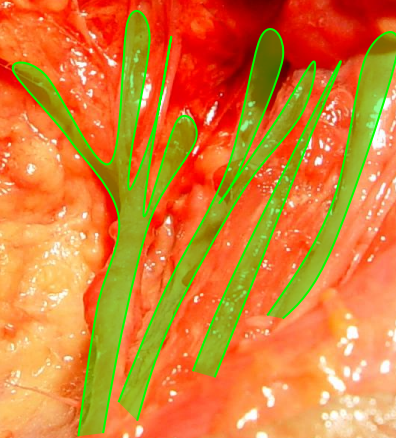


M López Soler  
O. Roda Murillo

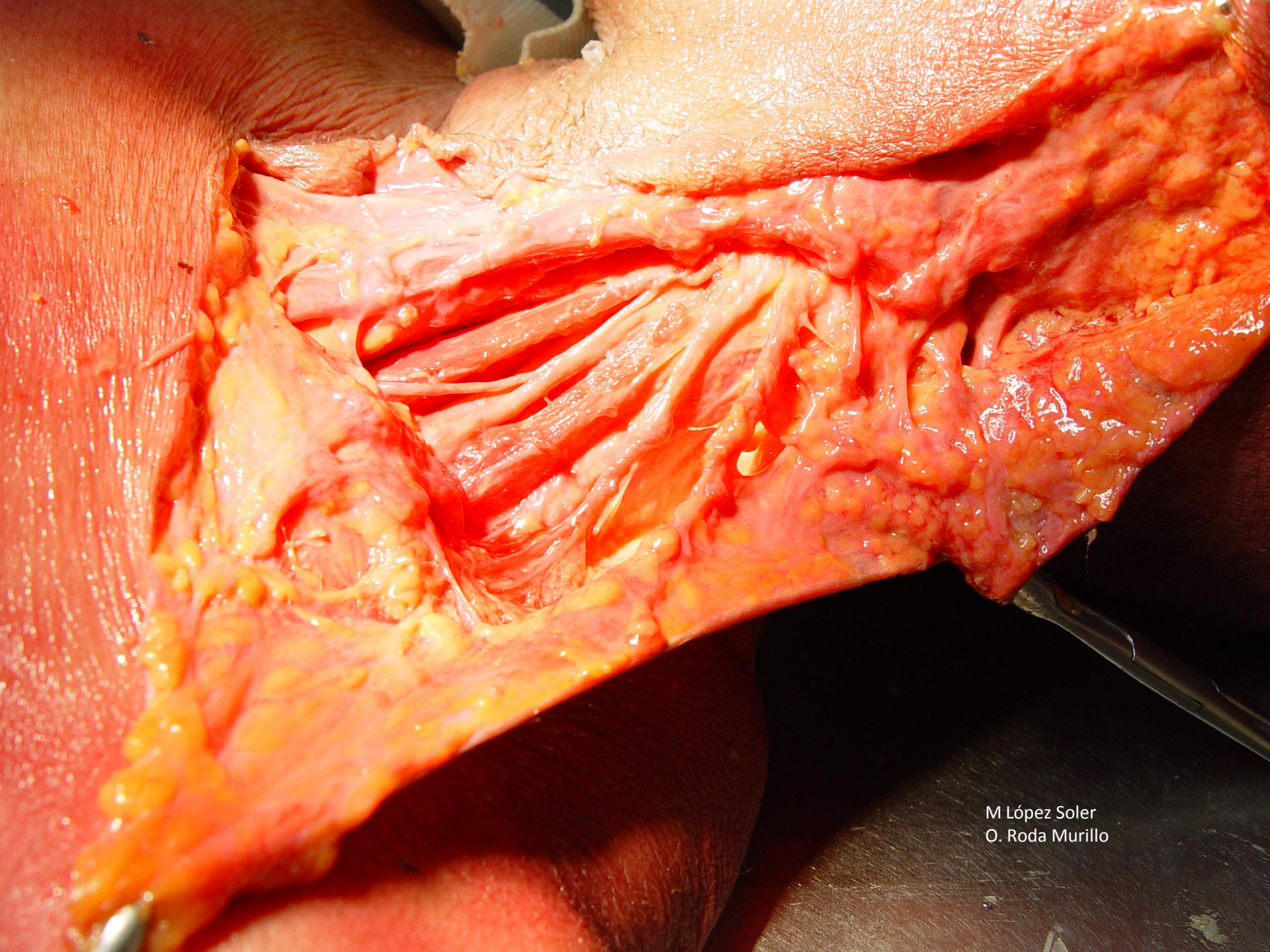


M López Soler  
O. Roda Murillo

**NERVIOS  
SUPRACLAVICULARES  
(Cutáneos)**



M López Soler  
O. Roda Murillo

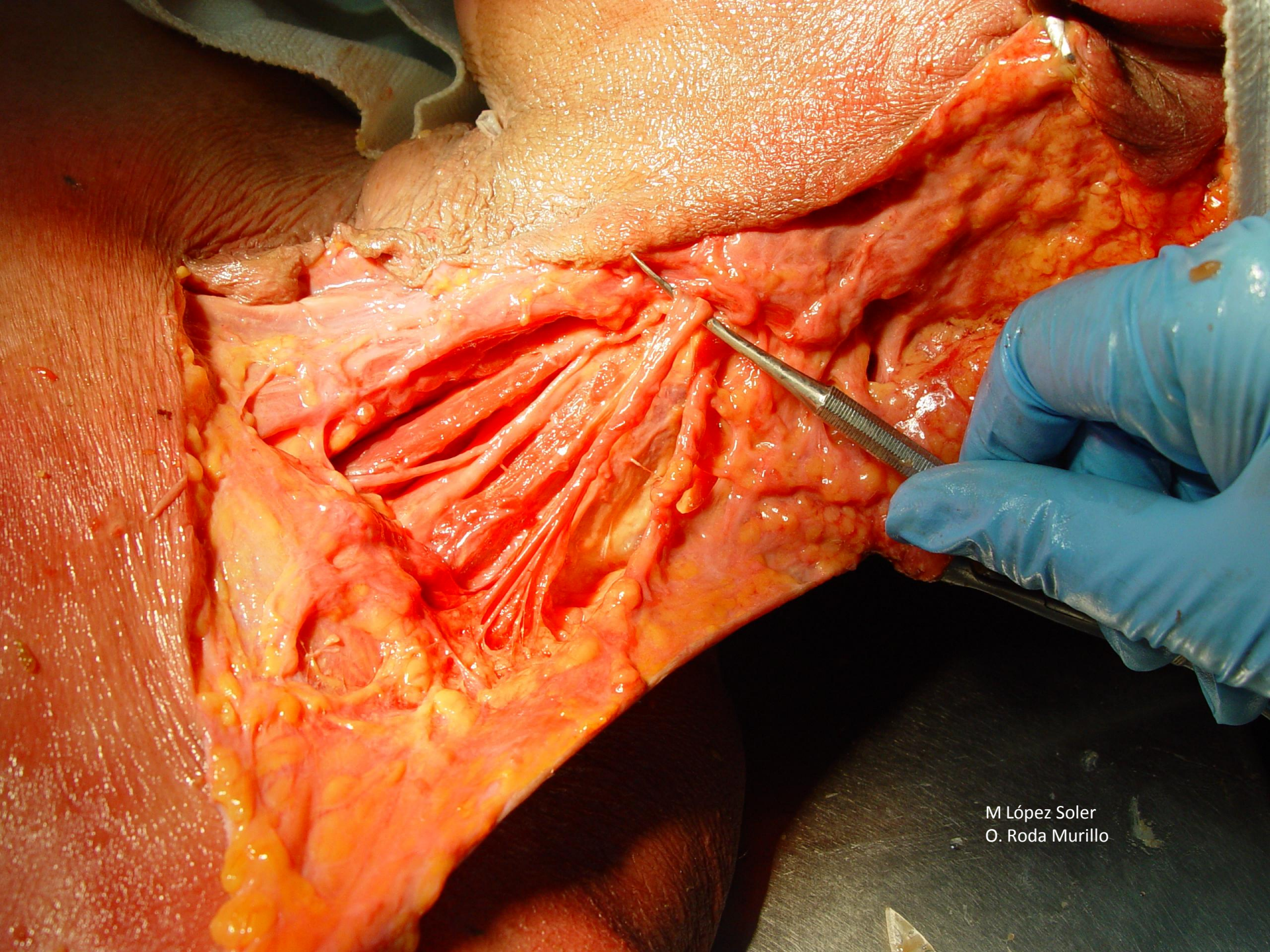


M López Soler  
O. Roda Murillo



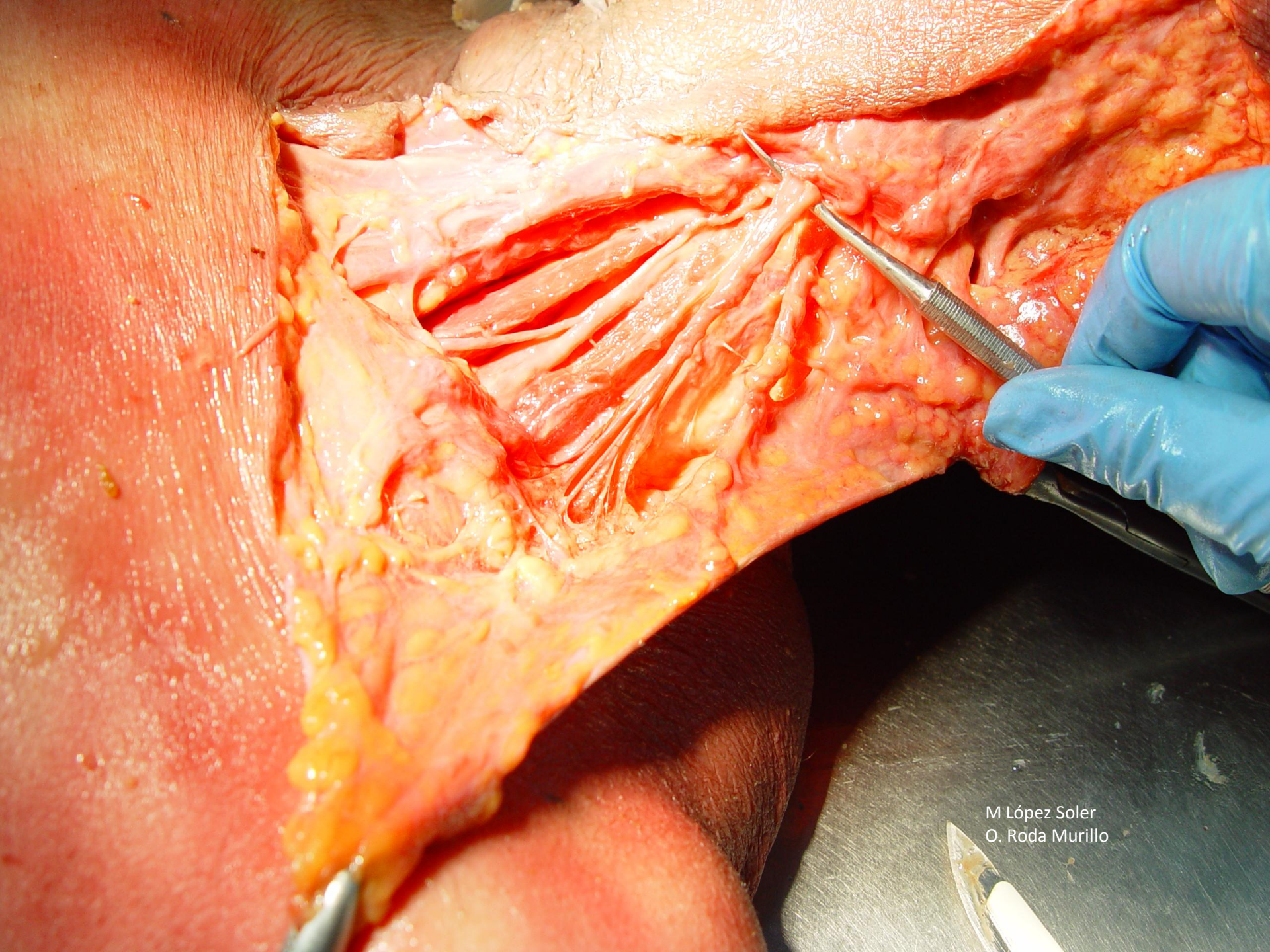
**NERVIOS  
SUPRACLAVICULARES  
(Cutáneos)**

M López Soler  
O. Roda Murillo

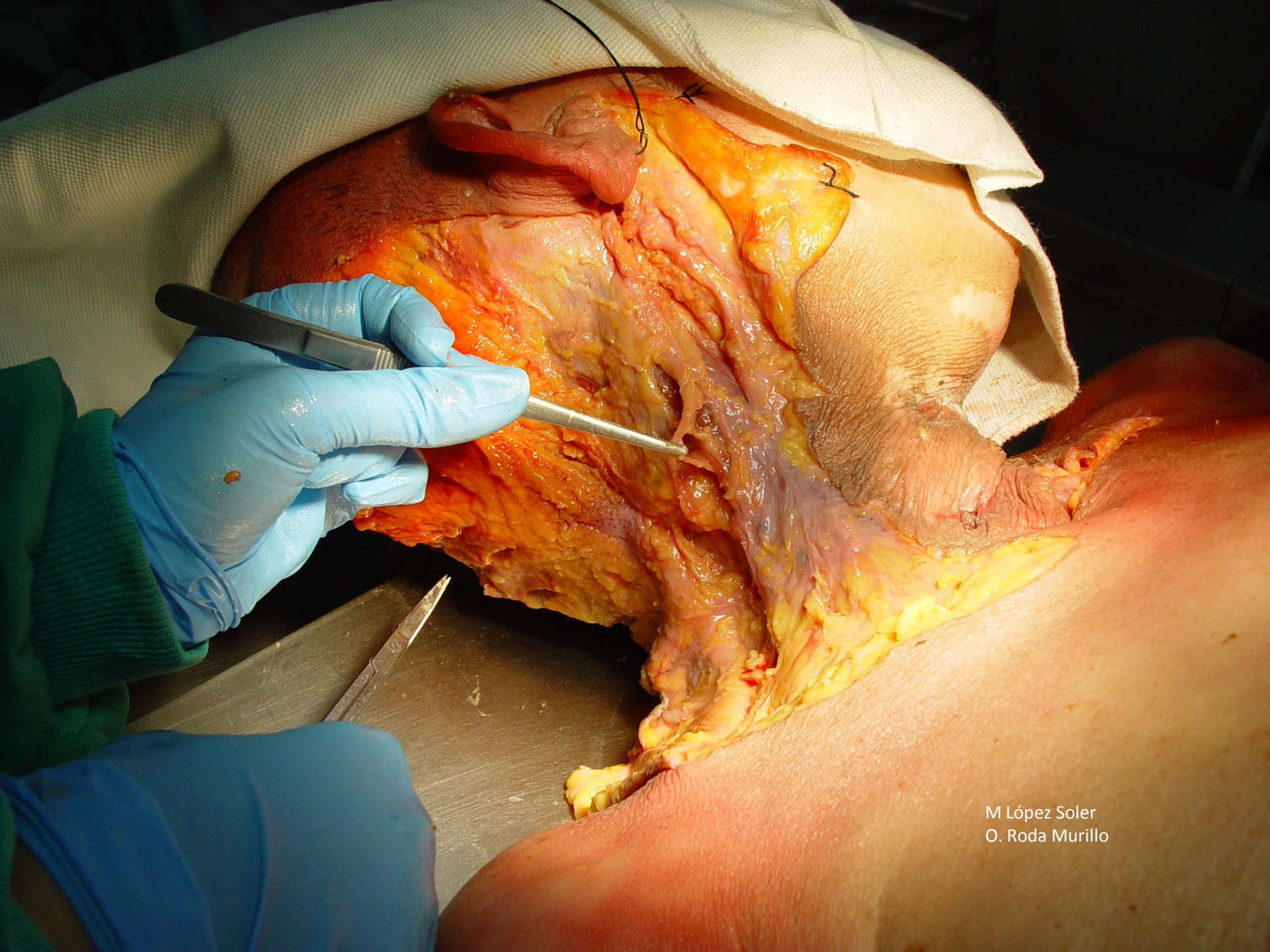


M López Soler  
O. Roda Murillo

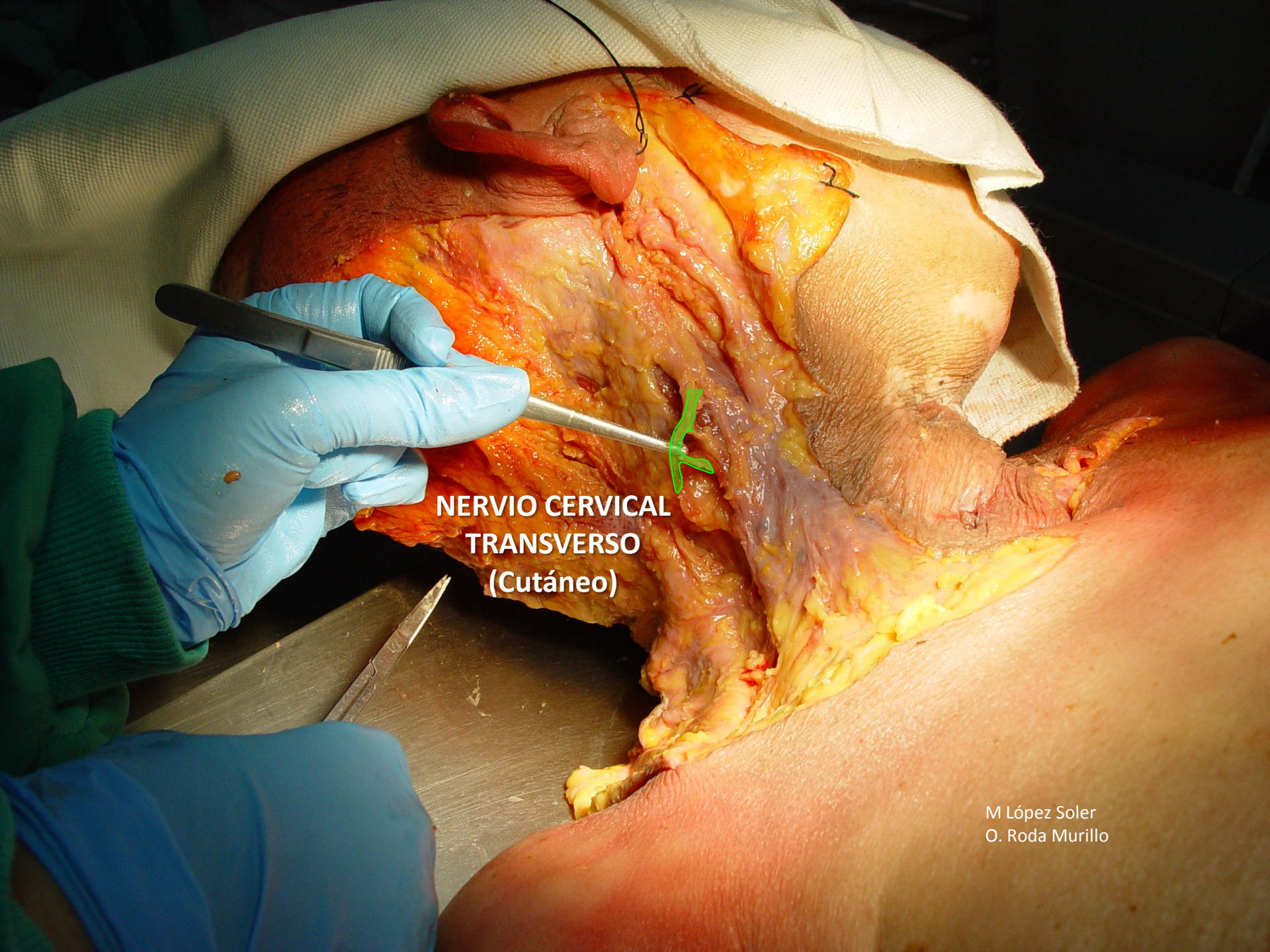




M López Soler  
O. Roda Murillo

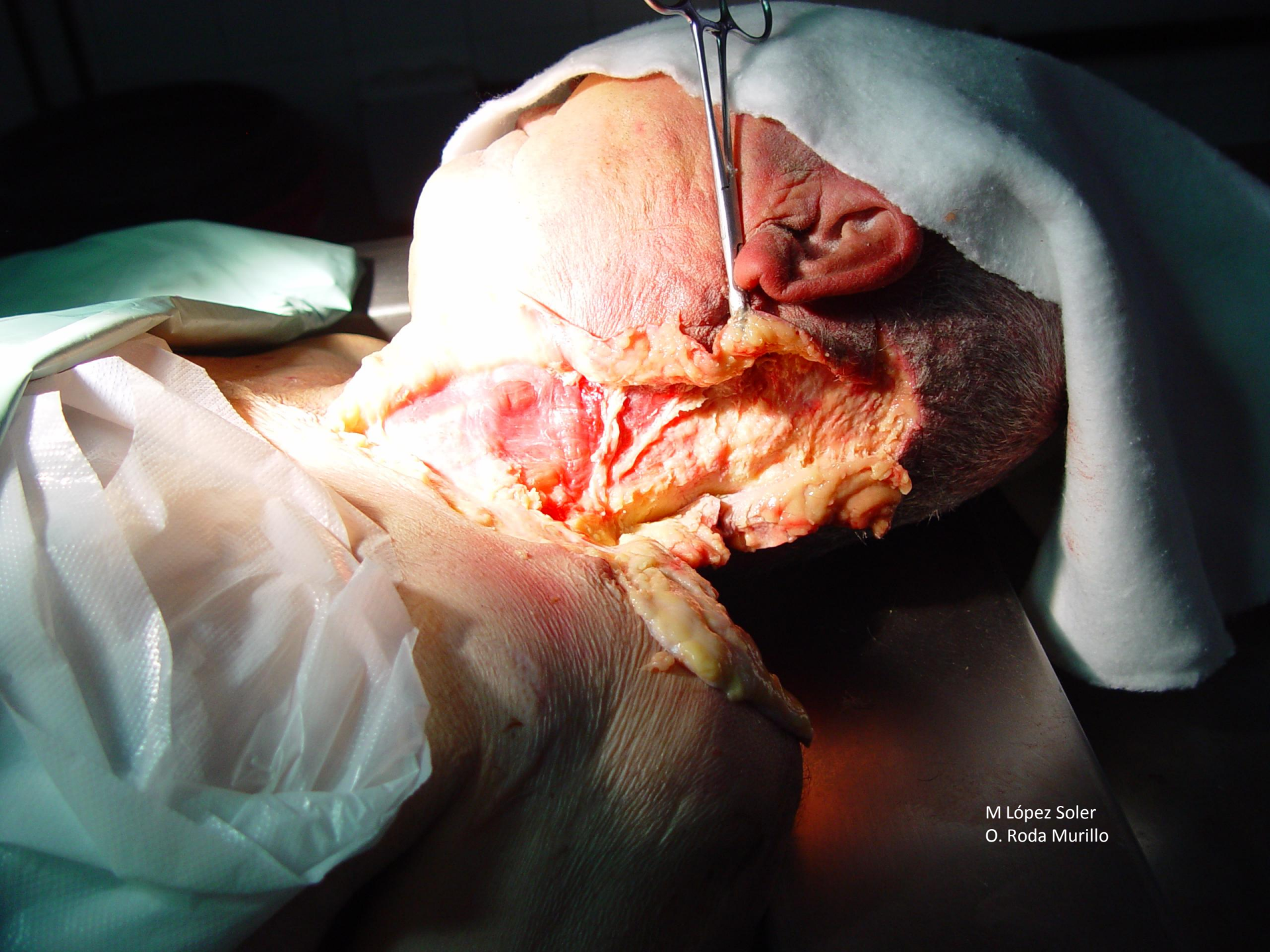


M López Soler  
O. Roda Murillo

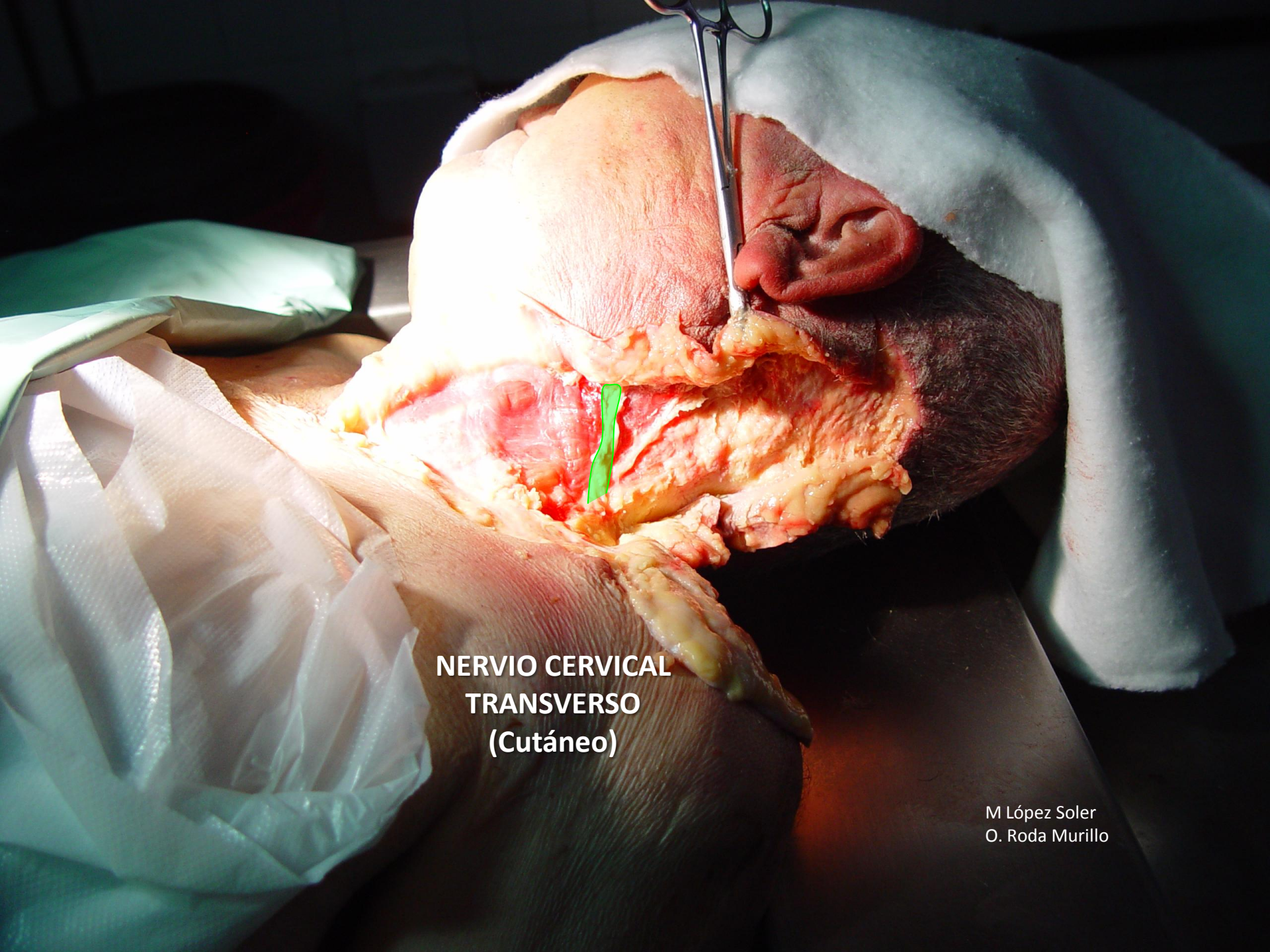


**NERVIO CERVICAL  
TRANSVERSO  
(Cutáneo)**

M López Soler  
O. Roda Murillo

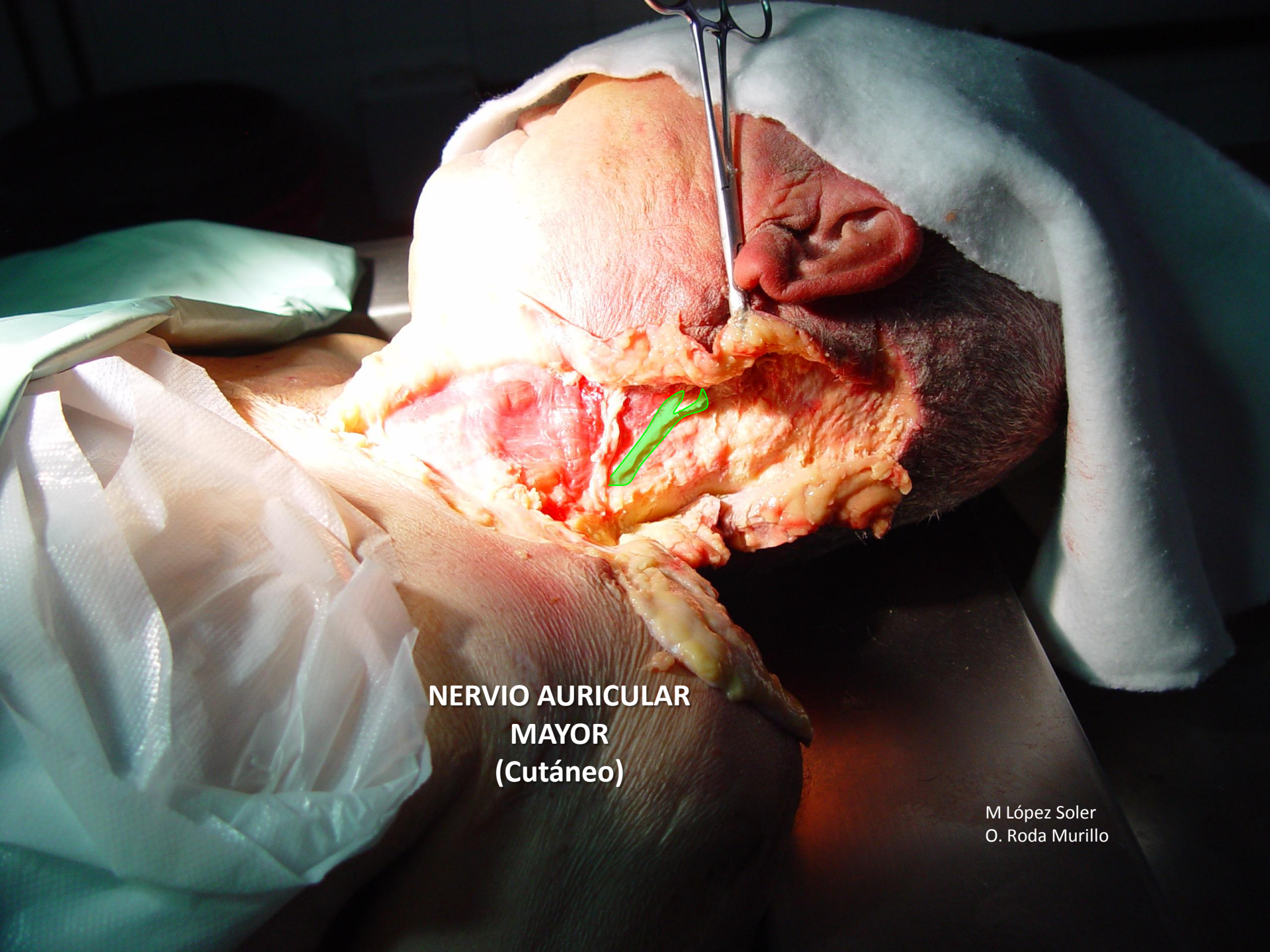

M López Soler  
O. Roda Murillo



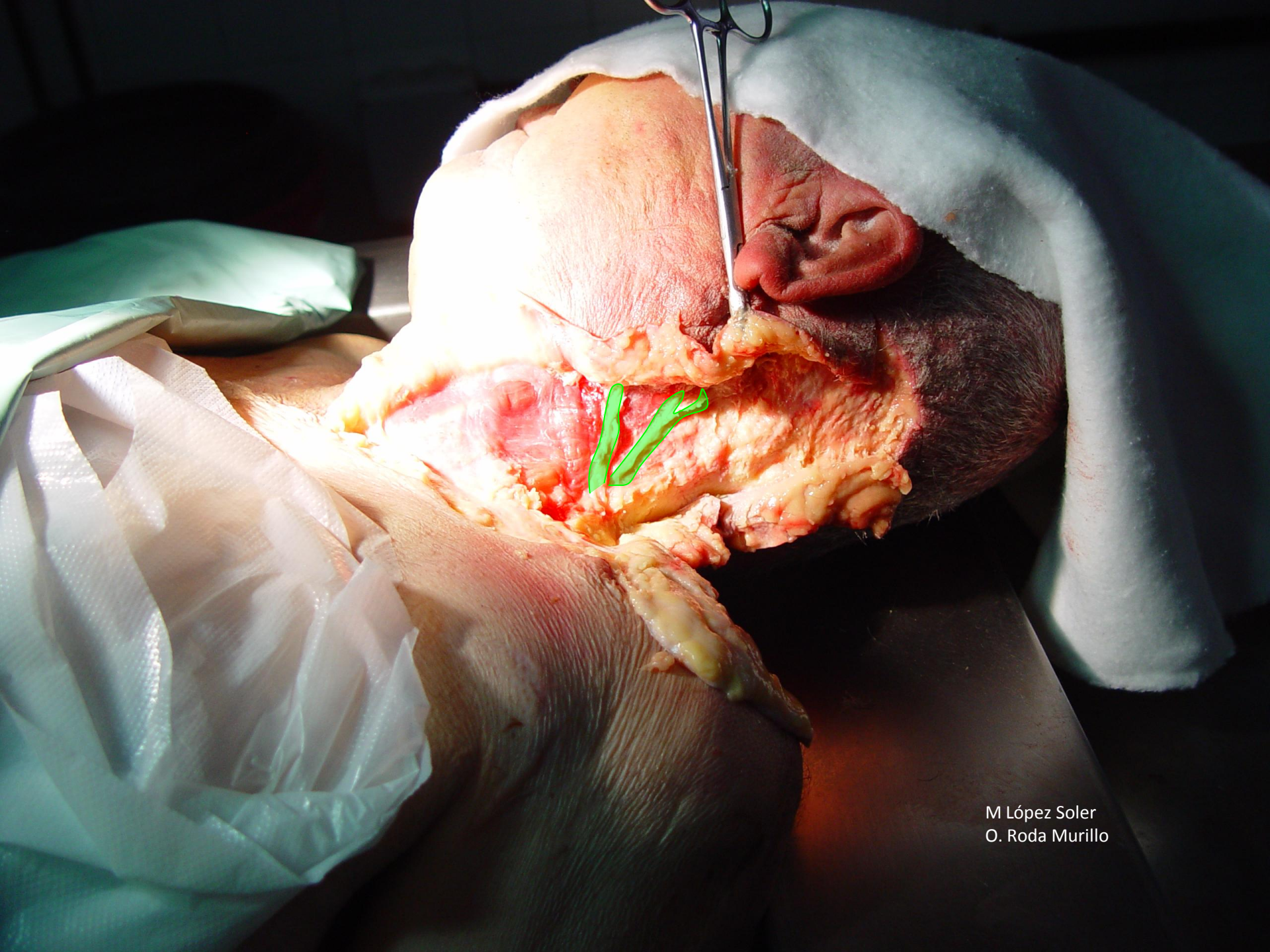
**NERVIO CERVICAL  
TRANSVERSO  
(Cutáneo)**

M López Soler  
O. Roda Murillo

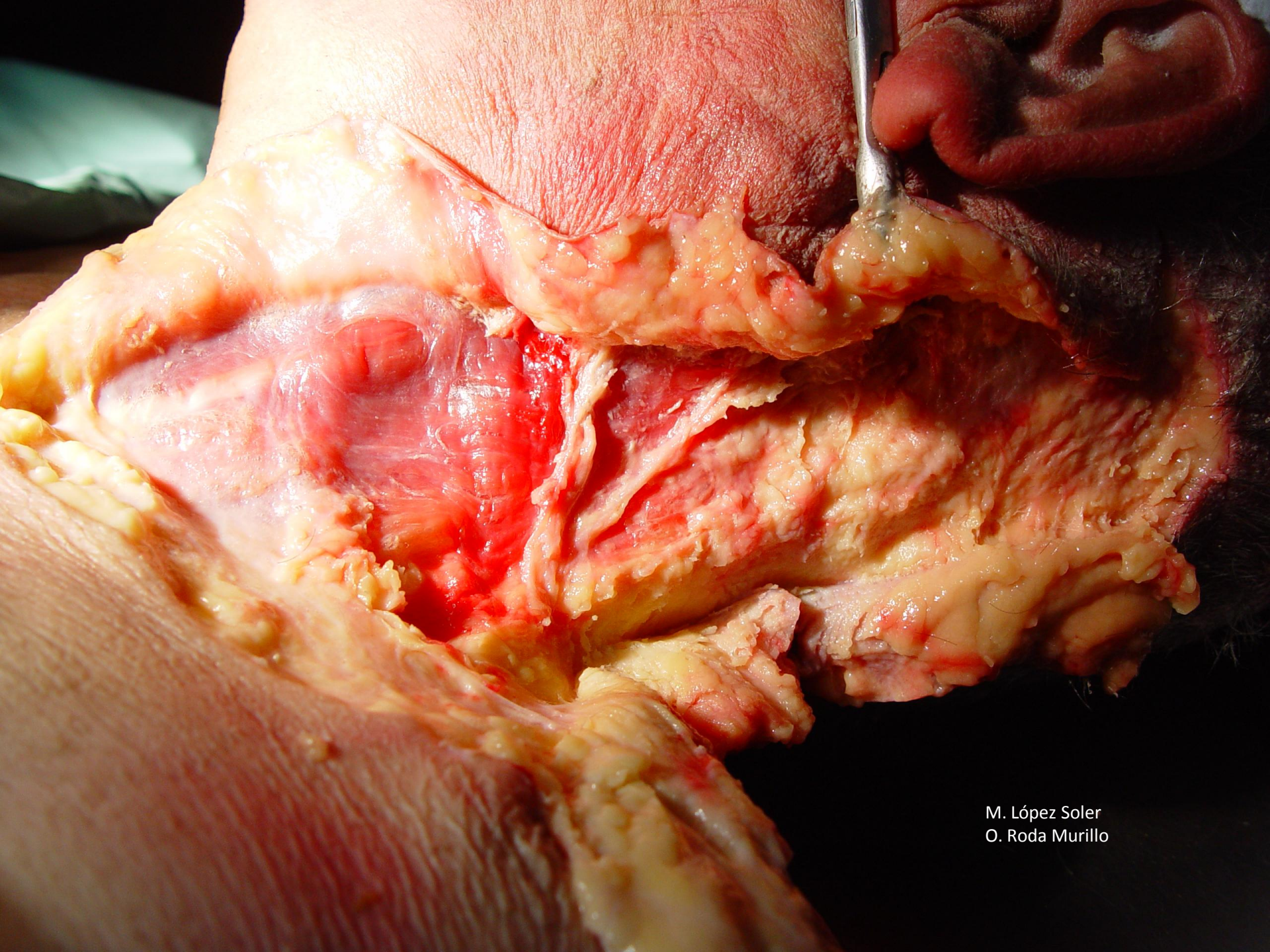


**NERVIO AURICULAR  
MAYOR  
(Cutáneo)**

M López Soler  
O. Roda Murillo

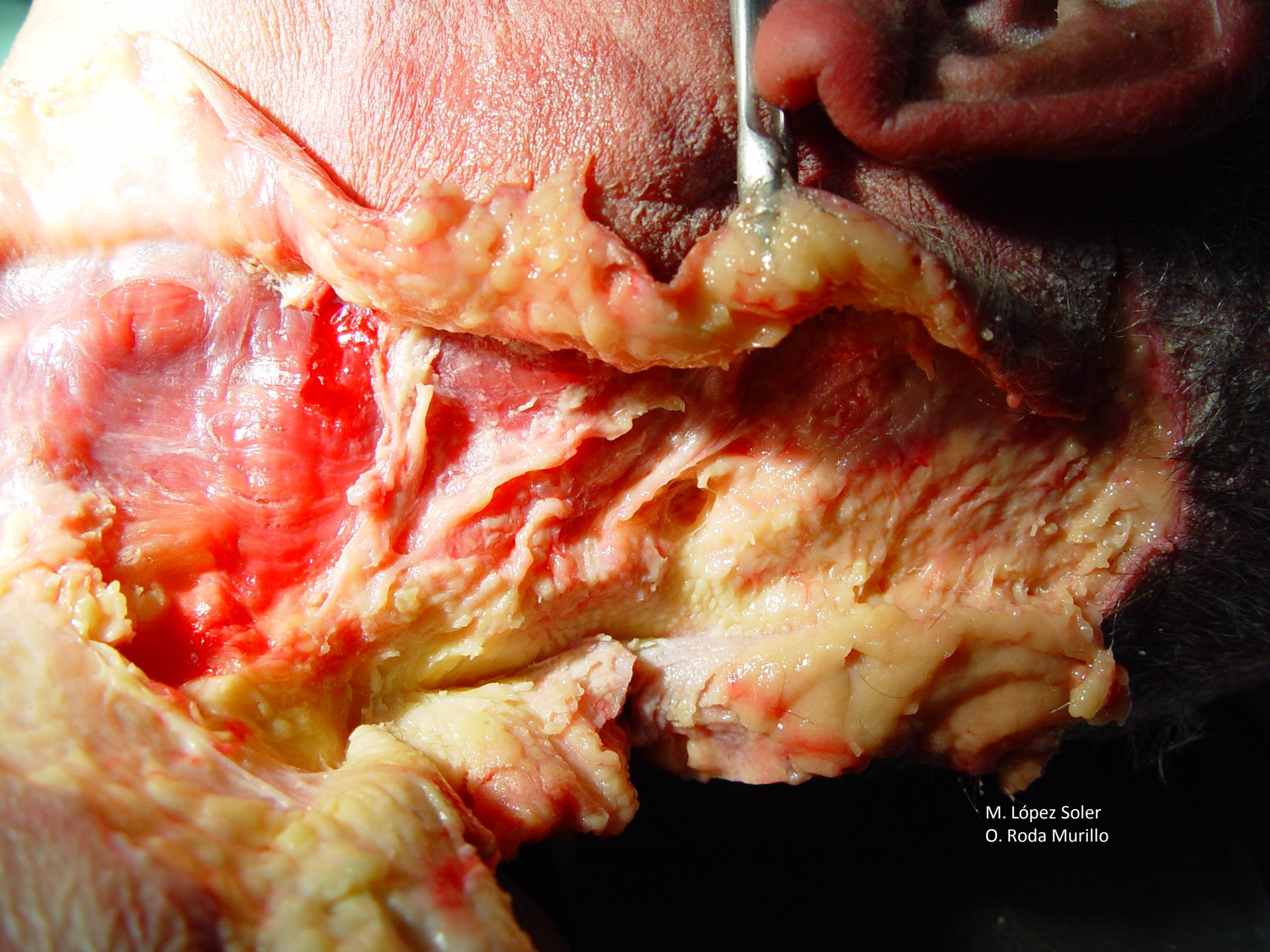


M López Soler  
O. Roda Murillo



M. López Soler  
O. Roda Murillo



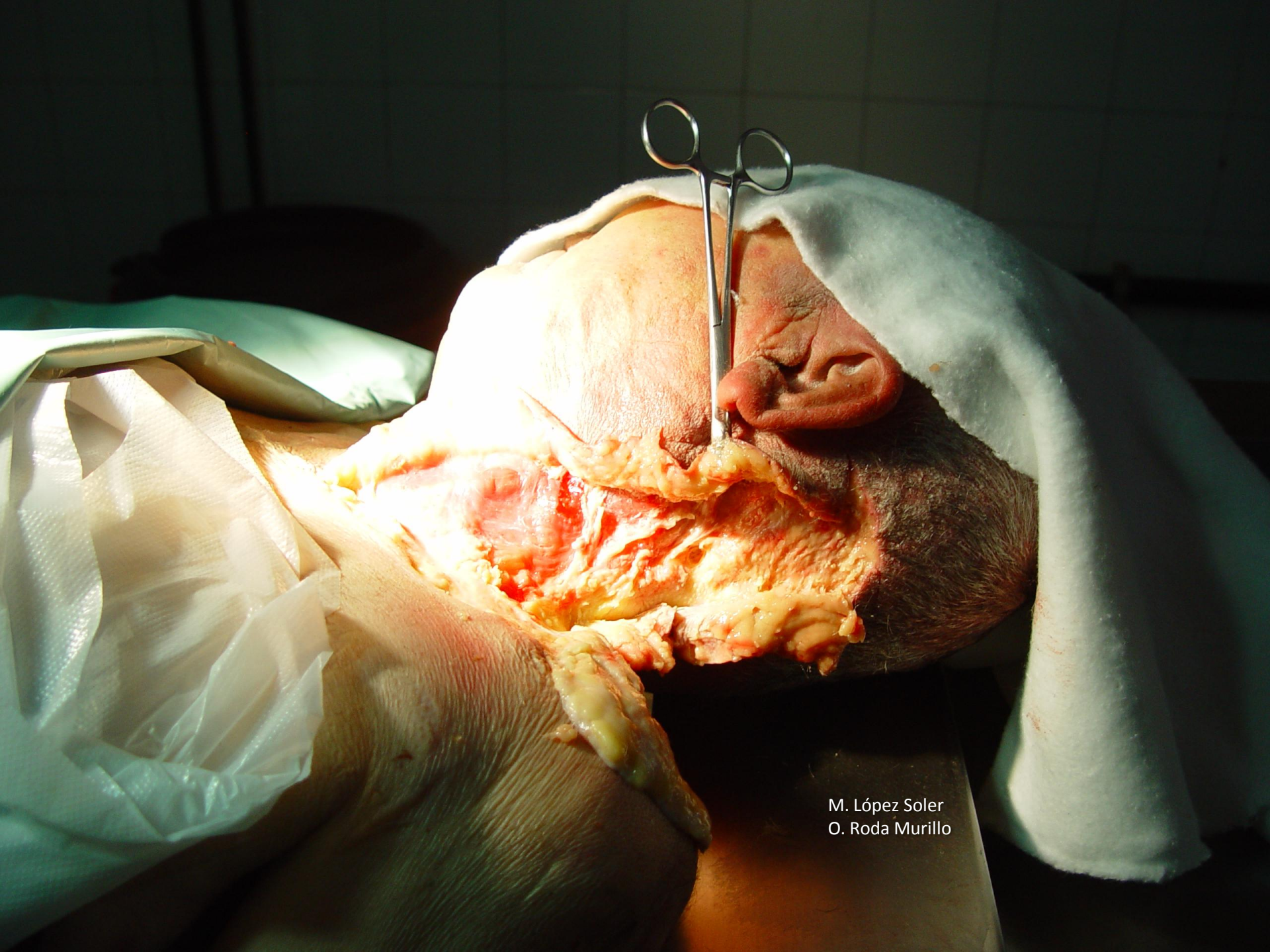


M. López Soler  
O. Roda Murillo

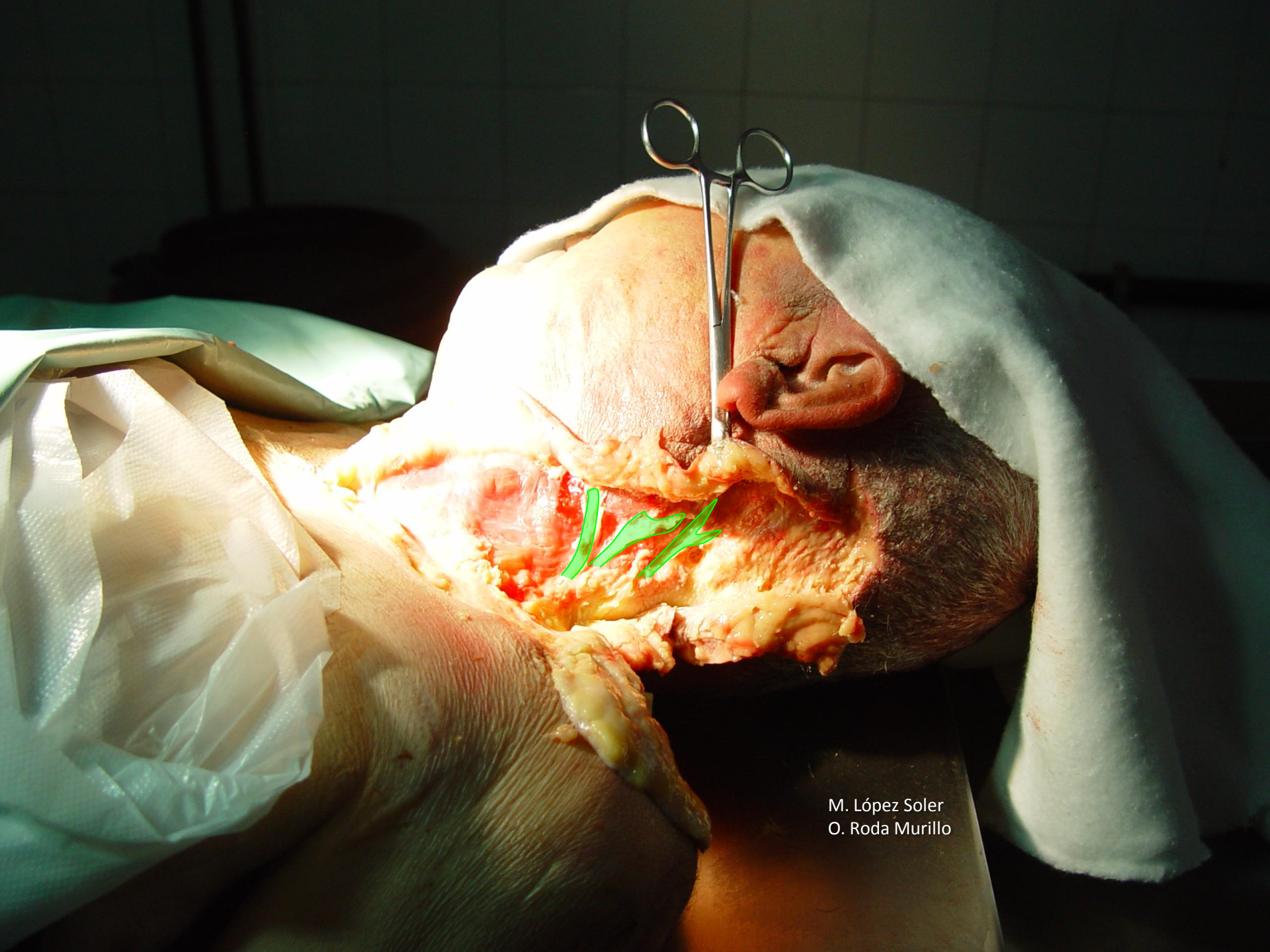
An anatomical dissection of the occipital region of a human head. The skin has been removed, revealing the underlying muscles and nerves. A green arrow points to a specific nerve. A surgical instrument is visible at the top of the dissection. The image is brightly lit, highlighting the various colors and textures of the tissues.

**NERVIO  
OCCIPITAL  
MENOR  
O MASTOIDEO  
(Cutáneo)**

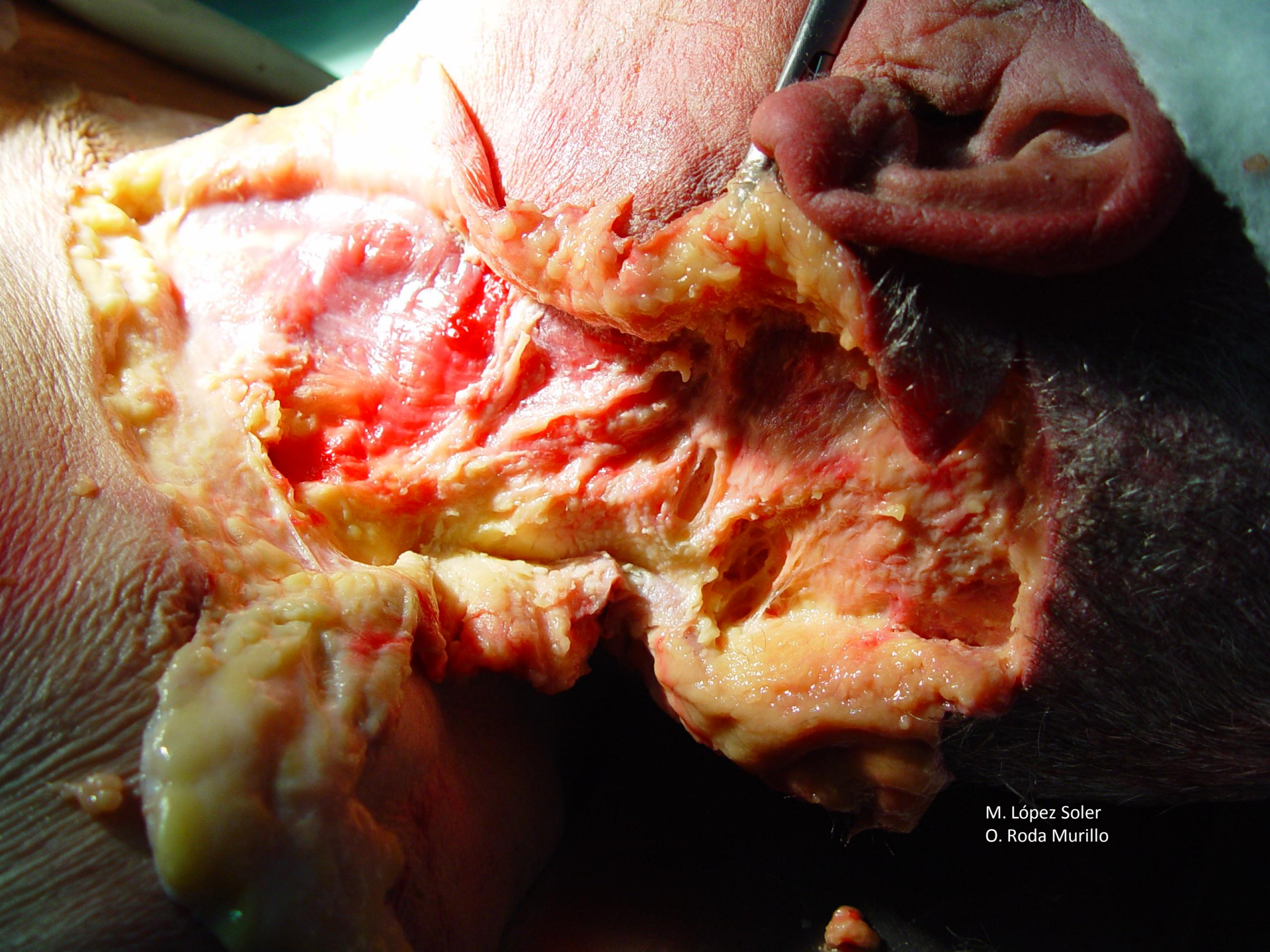
M. López Soler  
O. Roda Murillo



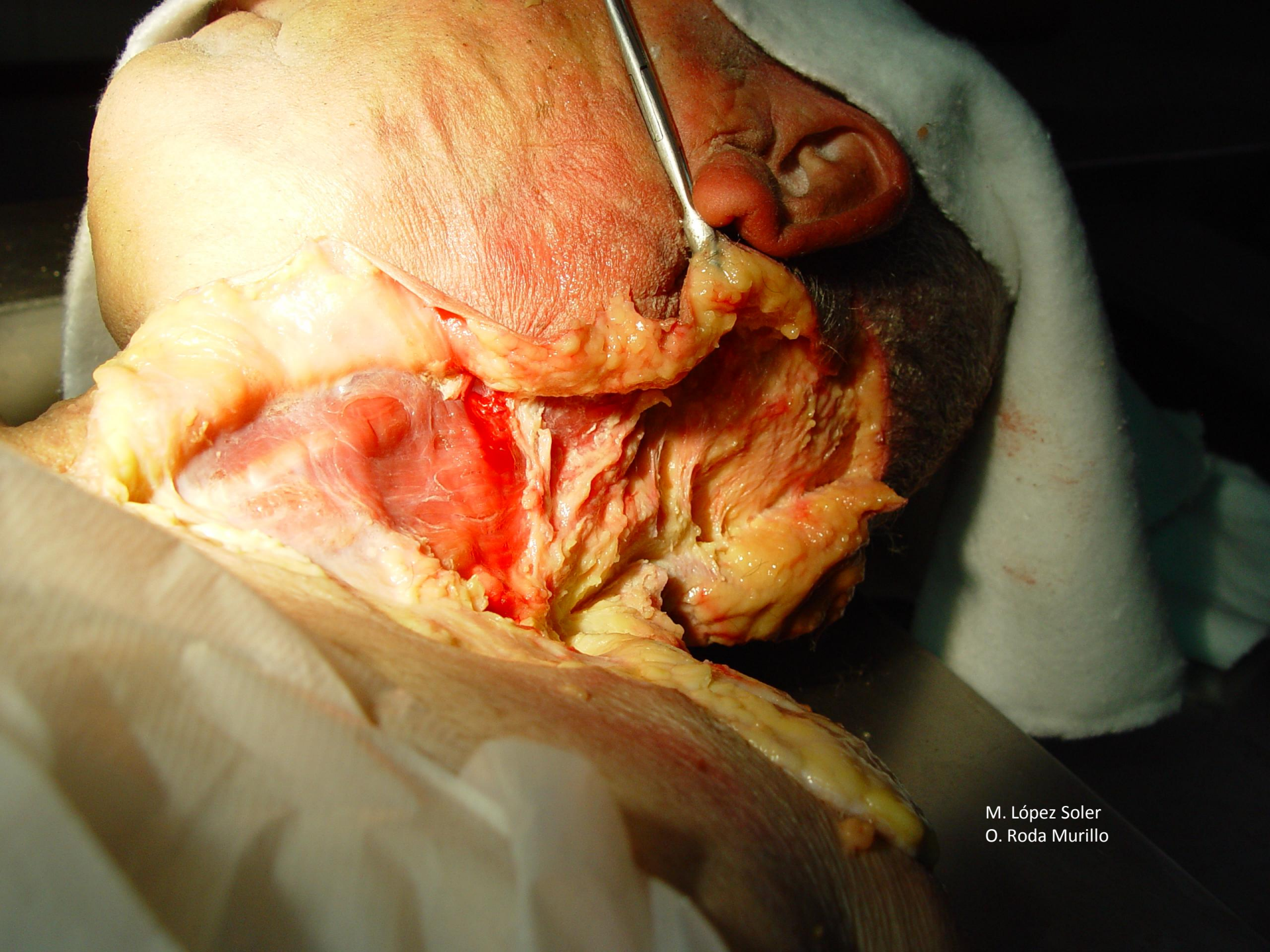
M. López Soler  
O. Roda Murillo



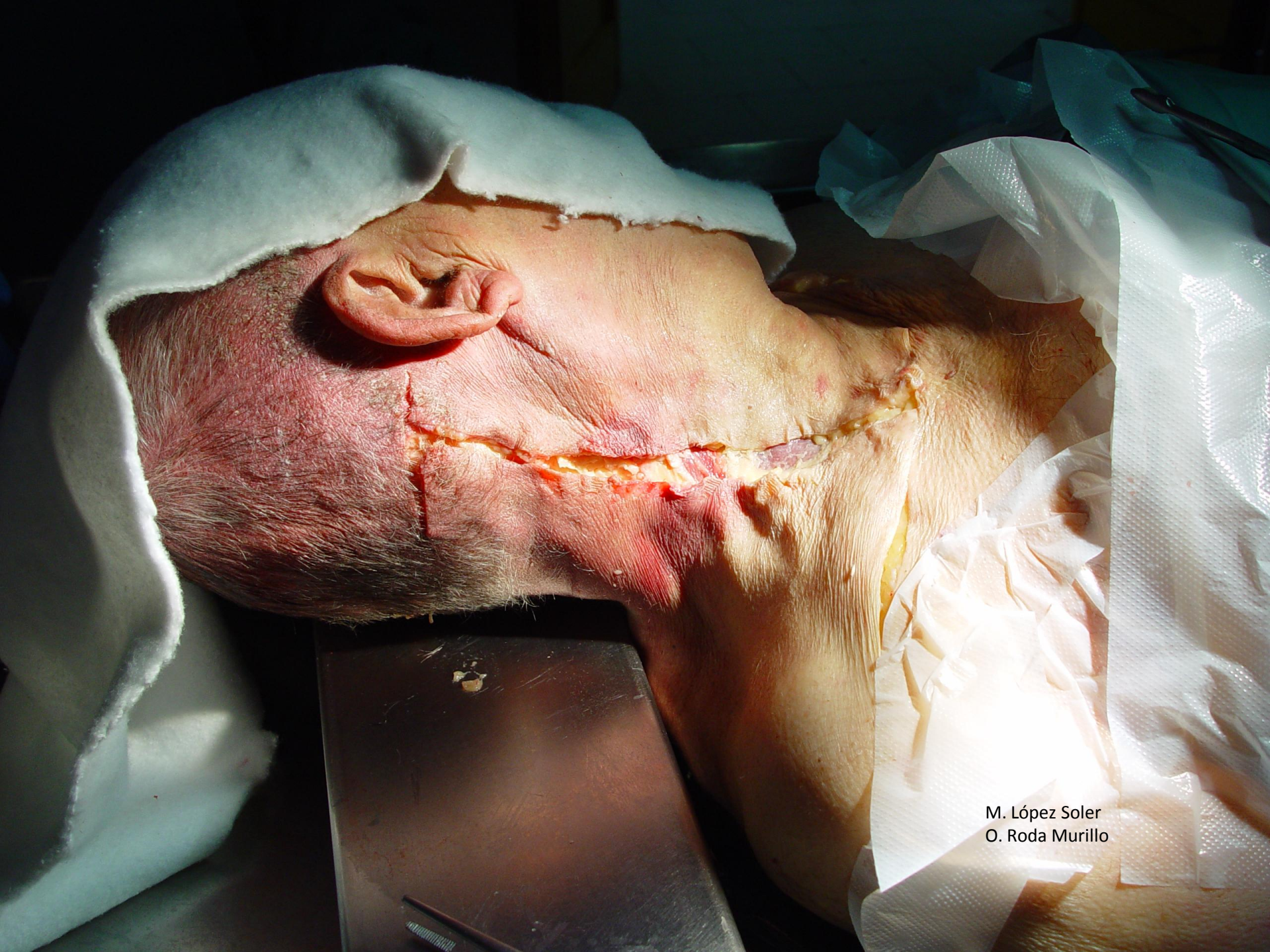M. López Soler  
O. Roda Murillo



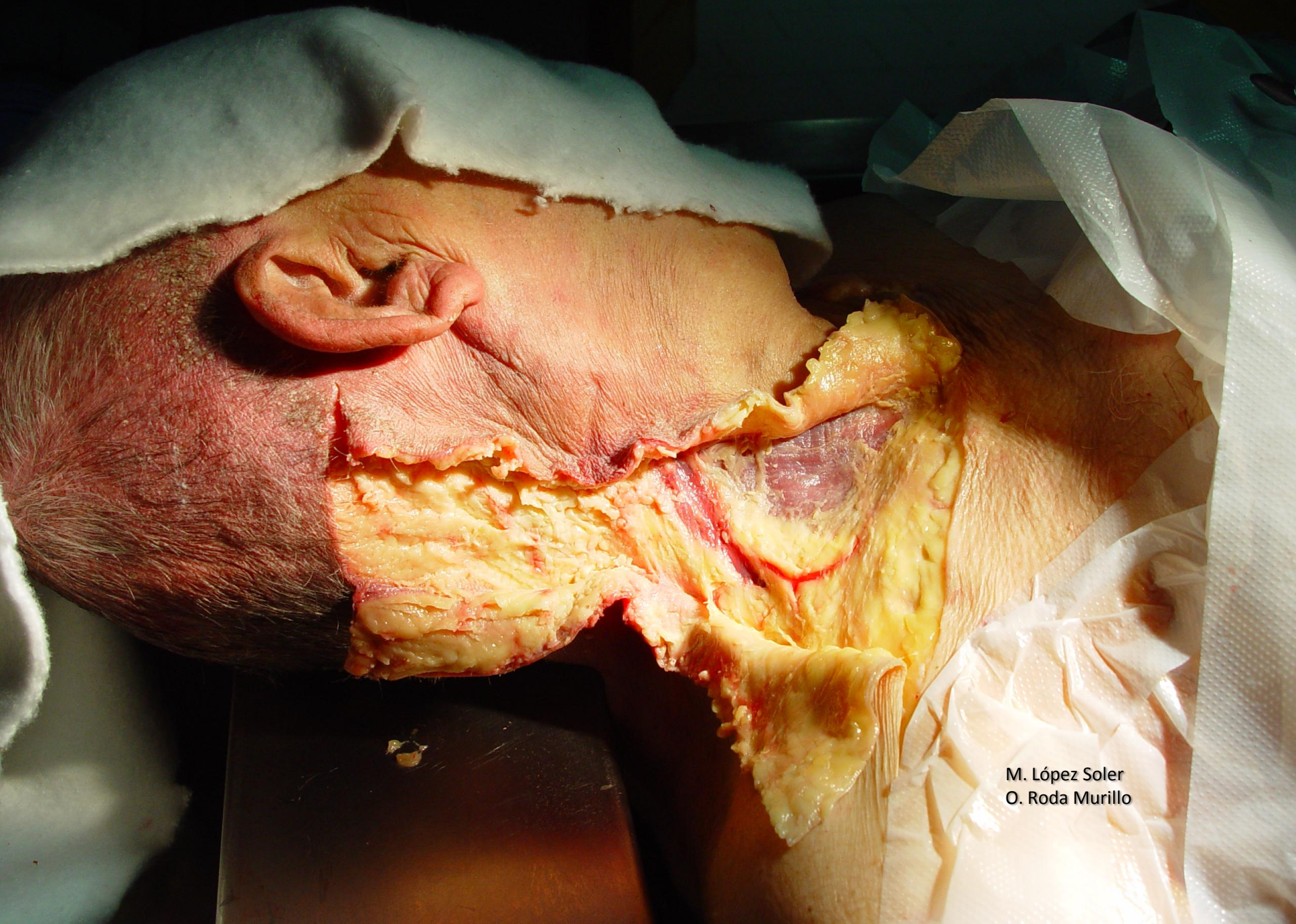
M. López Soler  
O. Roda Murillo



M. López Soler  
O. Roda Murillo

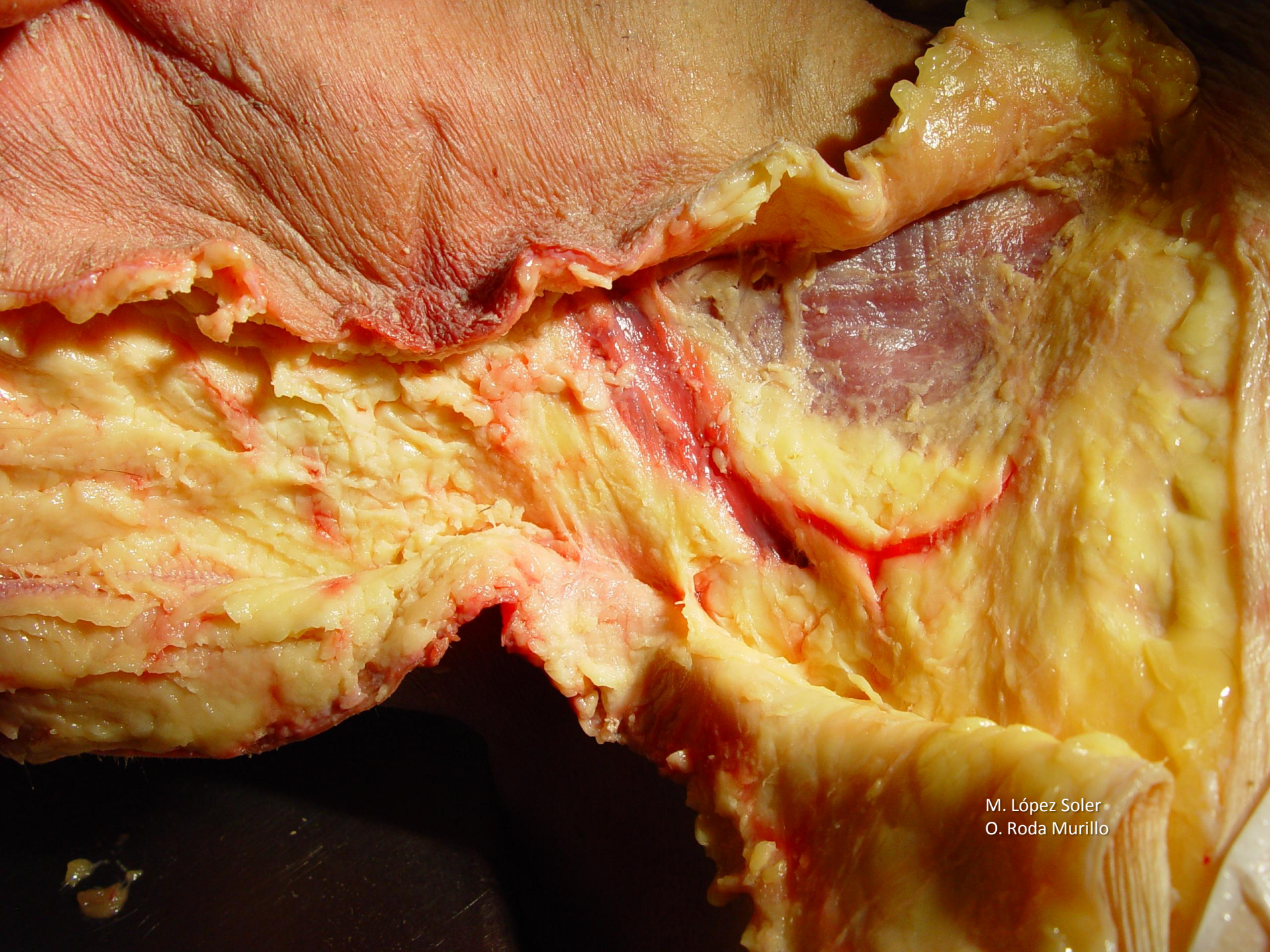


M. López Soler  
O. Roda Murillo

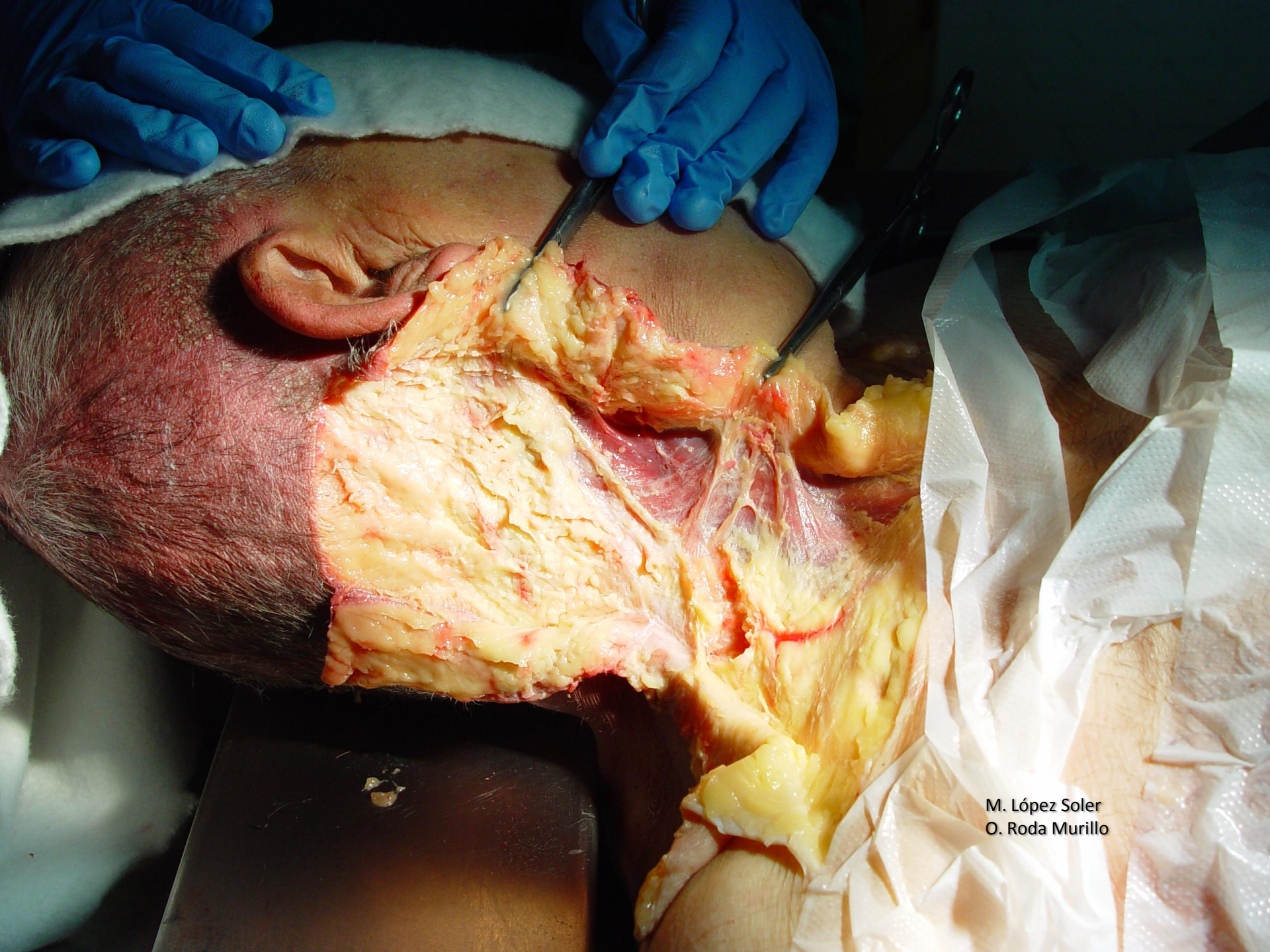

M. López Soler  
O. Roda Murillo

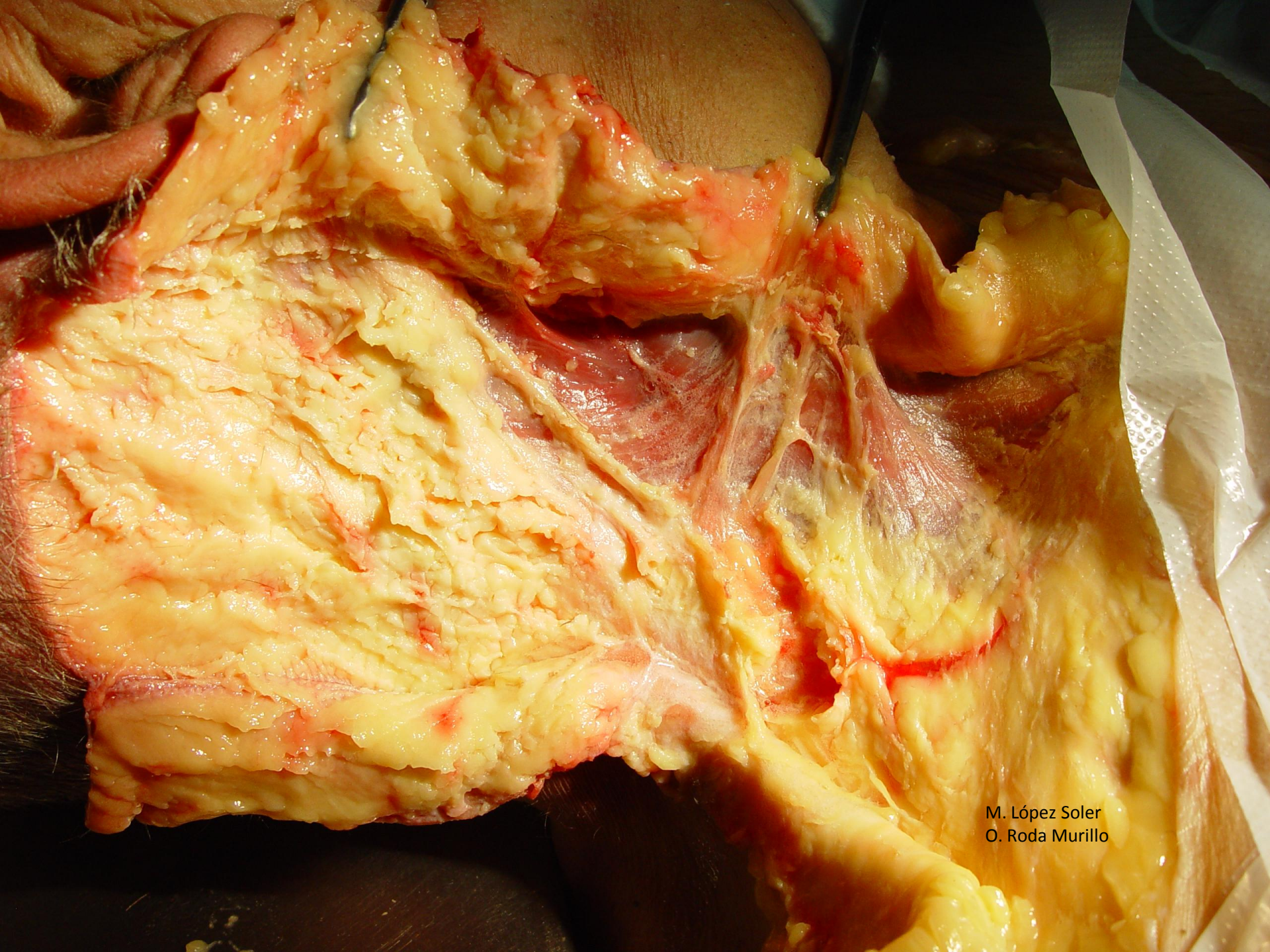




M. López Soler  
O. Roda Murillo



M. López Soler  
O. Roda Murillo



M. López Soler  
O. Roda Murillo

An anatomical dissection of the human scalp, showing the greater auricular nerve (cutaneous) highlighted with a green line. The dissection reveals the underlying musculature and connective tissue layers. The nerve is shown running through the tissue, and the surrounding structures are clearly visible. The dissection is performed on a patient's head, with the scalp reflected to expose the underlying anatomy.

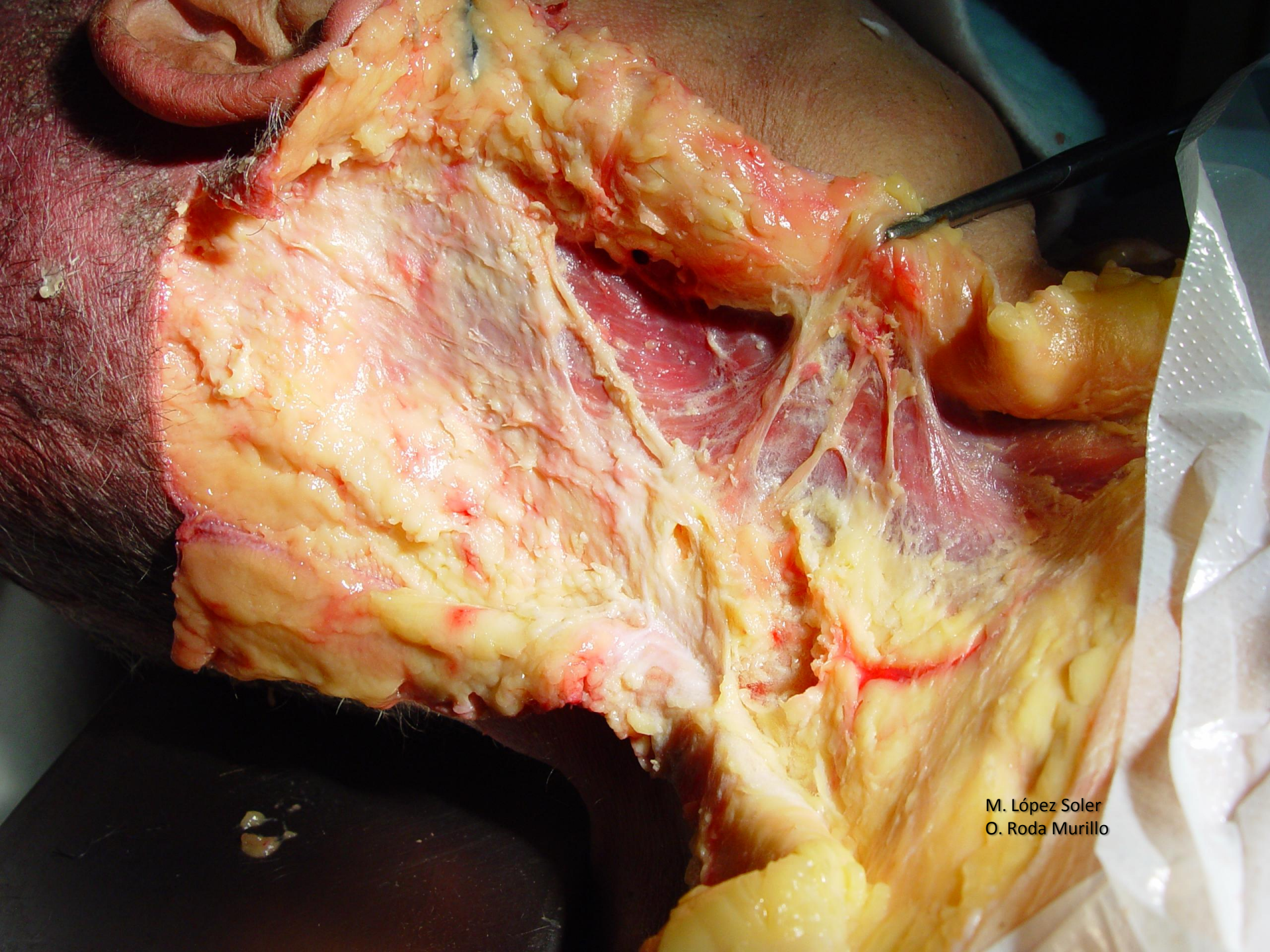
**NERVIO AURICULAR  
MAYOR  
(Cutáneo)**

M. López Soler  
O. Roda Murillo

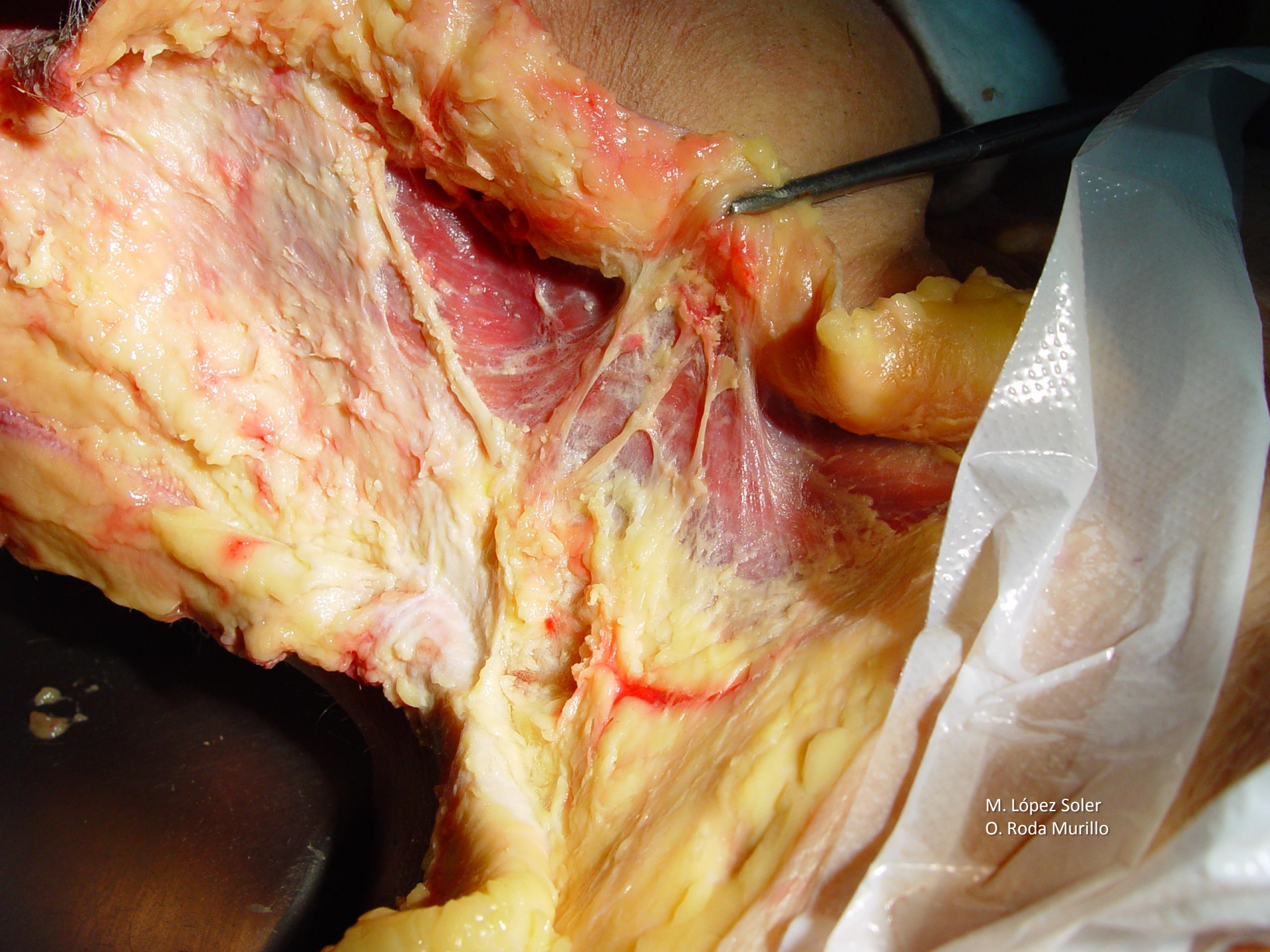
An anatomical dissection of a human neck, showing the cutaneous cervical transverse nerve. The nerve is highlighted with a green arrow. The dissection reveals the underlying musculature and connective tissue layers. The nerve is seen running horizontally across the neck, just below the skin surface. The surrounding tissue is yellowish and fibrous, with some red areas indicating blood vessels or muscle fibers. The dissection is performed on a wooden surface, and a white paper towel is visible on the right side.

**NERVIO CERVICAL  
TRANSVERSO  
(Cutáneo)**

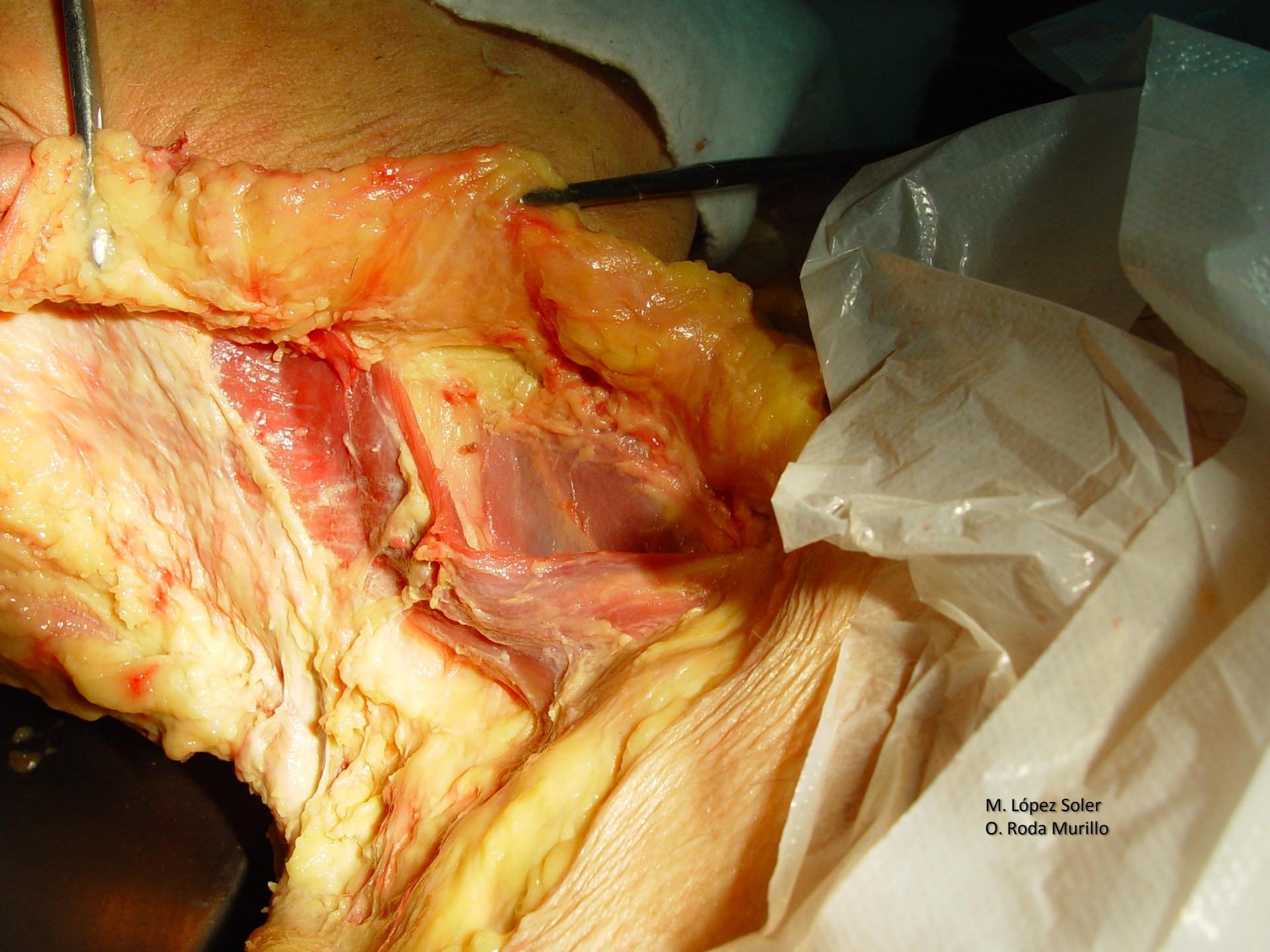
M. López Soler  
O. Roda Murillo



M. López Soler  
O. Roda Murillo



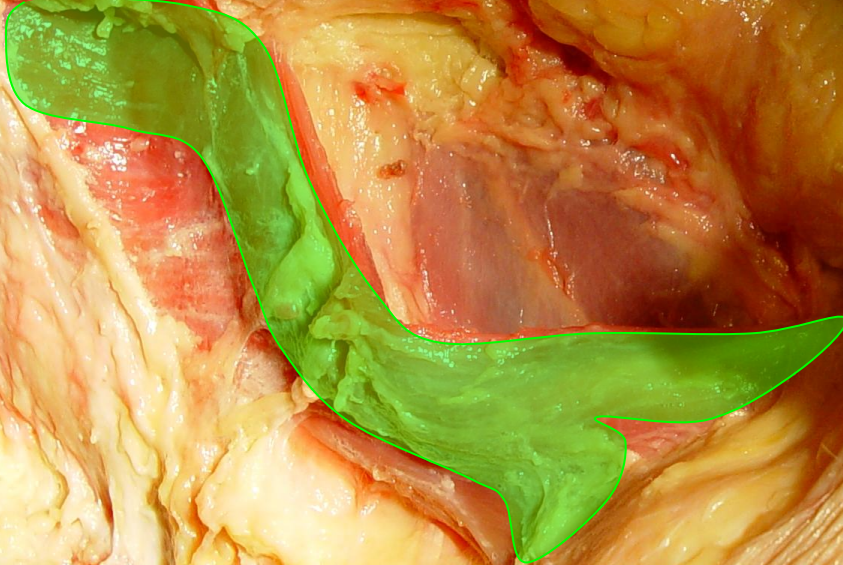
M. López Soler  
O. Roda Murillo



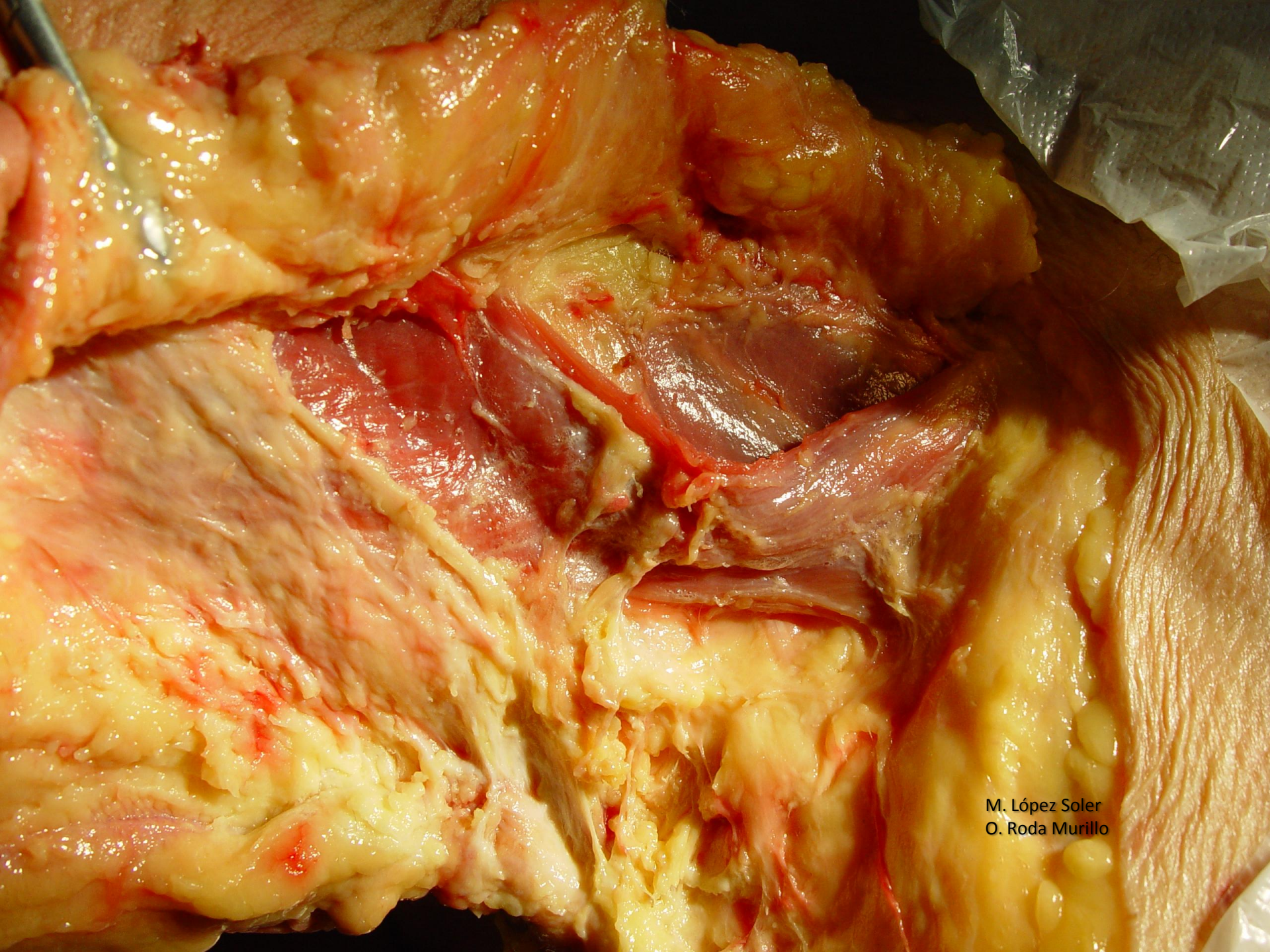
M. López Soler  
O. Roda Murillo



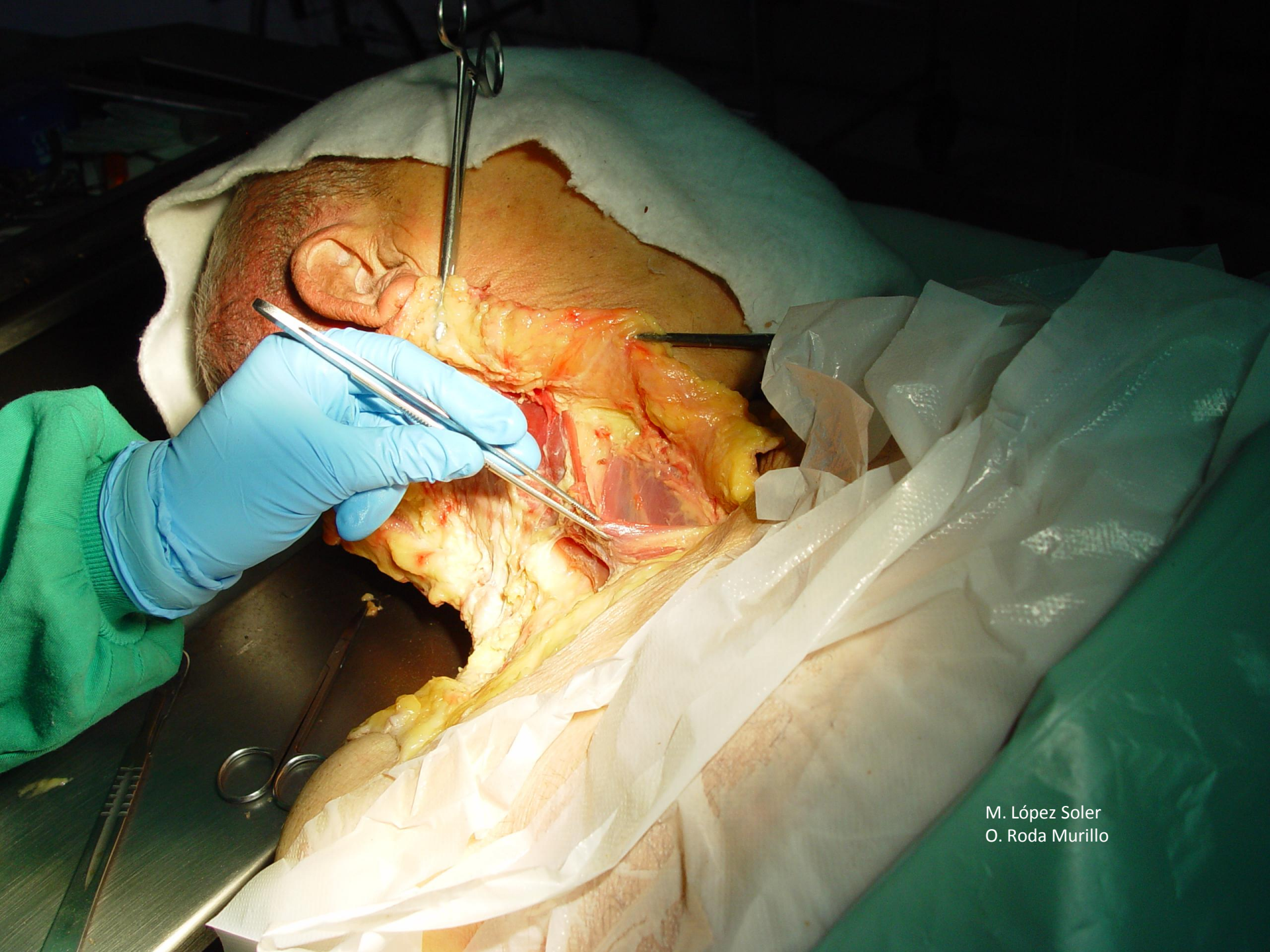**MÚSCULO ESTERNOCLEIDOMASTOIDEO**



M. López Soler  
O. Roda Murillo

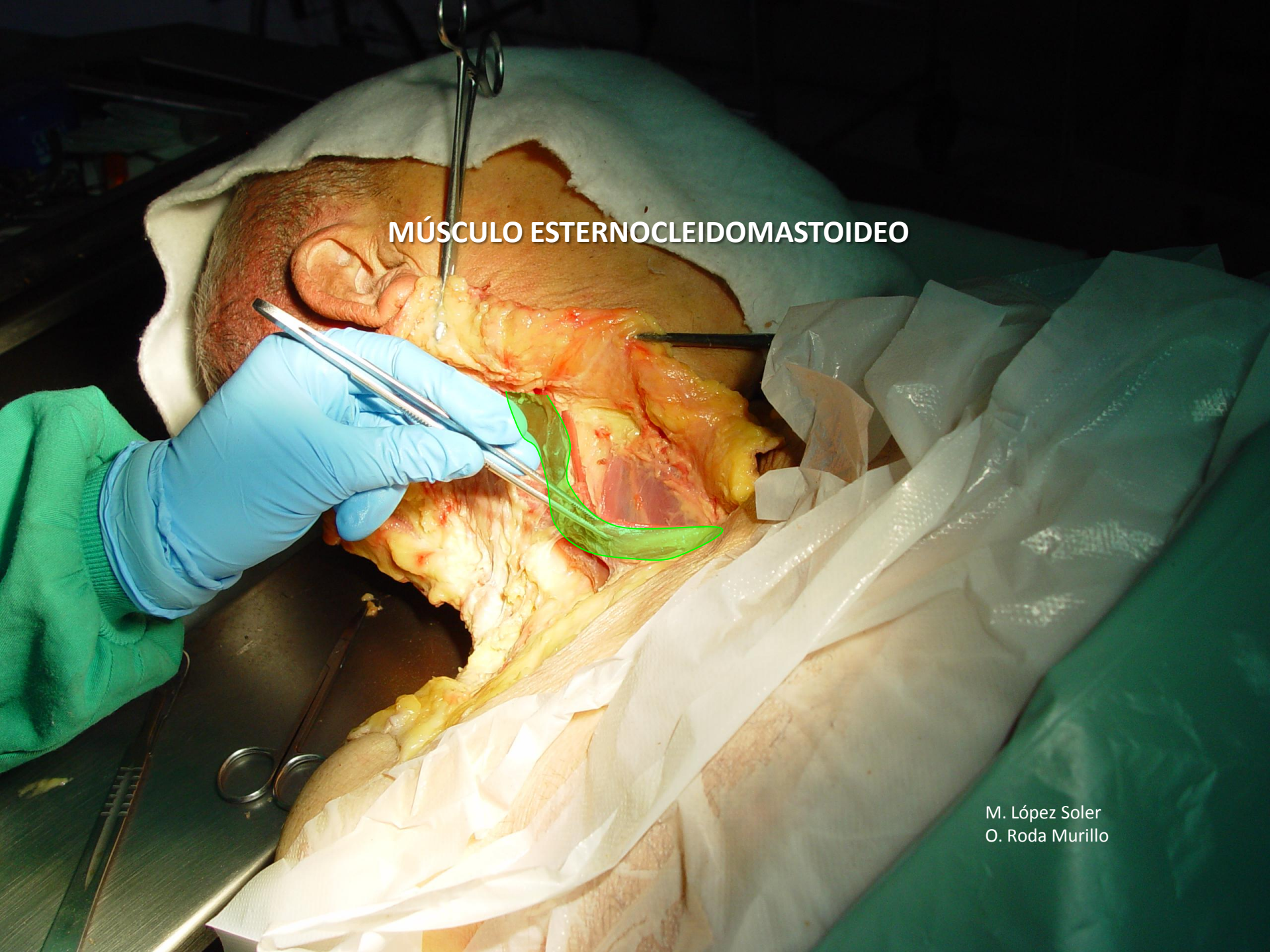

M. López Soler  
O. Roda Murillo

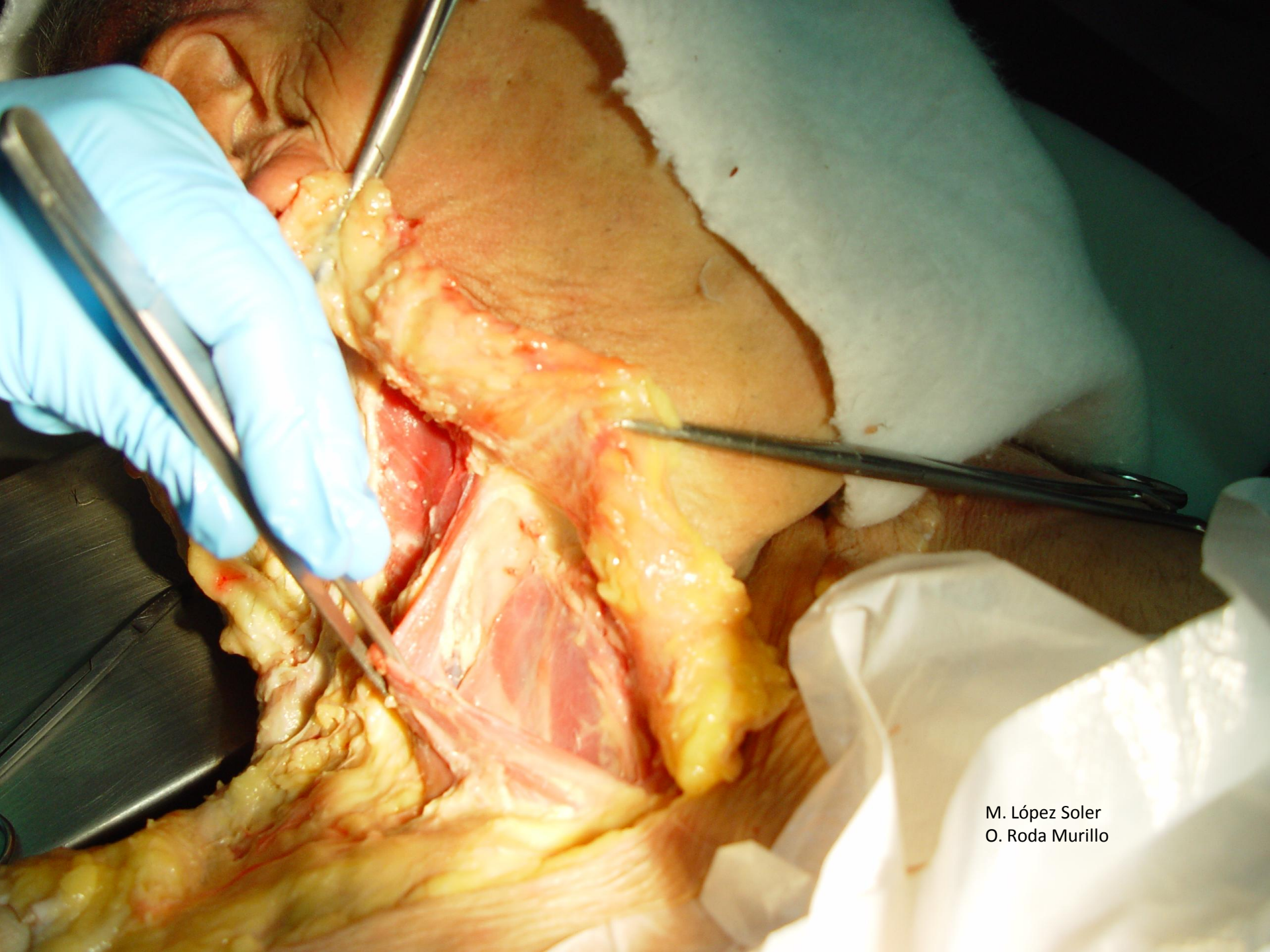


M. López Soler  
O. Roda Murillo

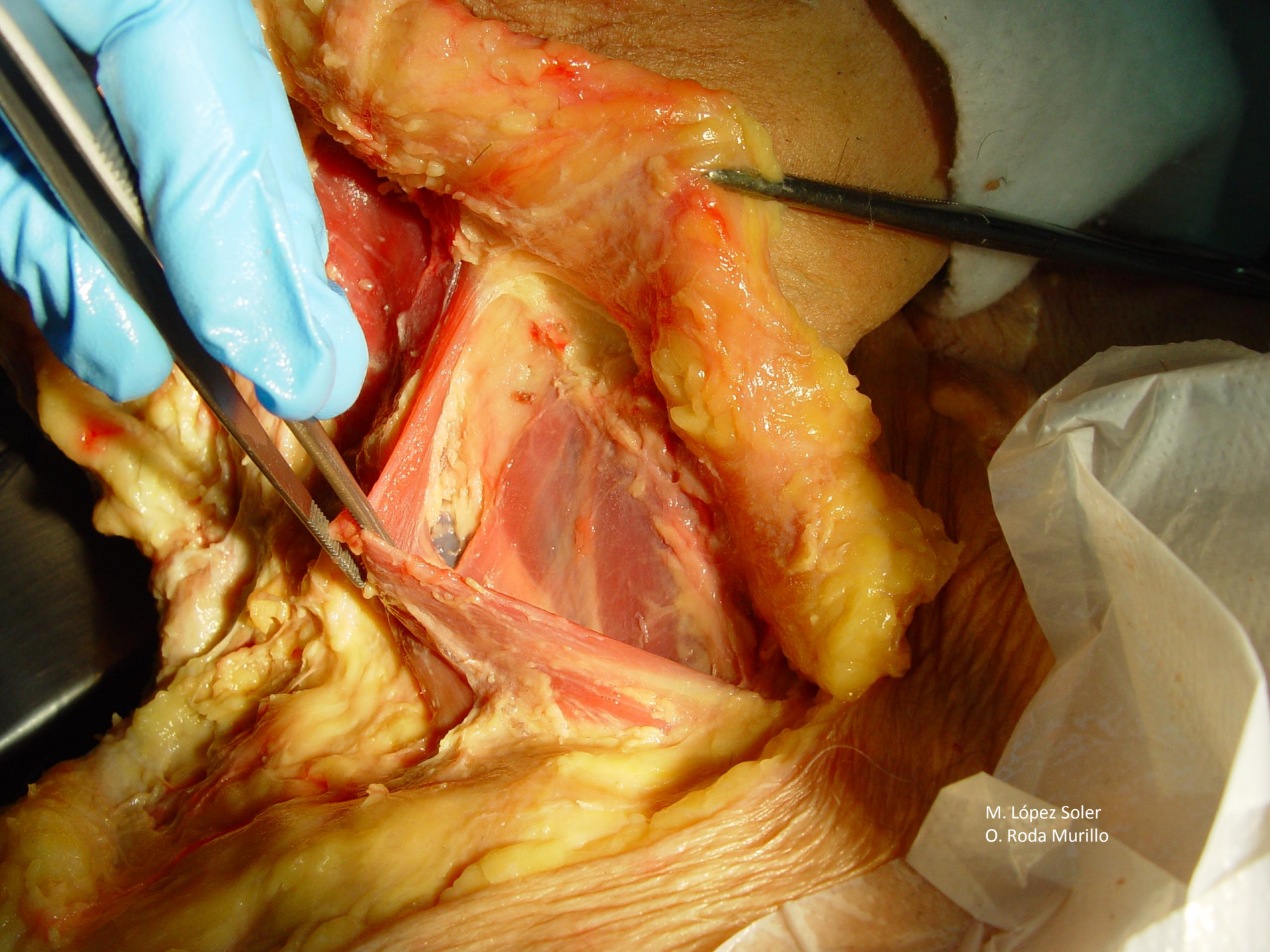
**MÚSCULO ESTERNOCLEIDOMASTOIDEO**



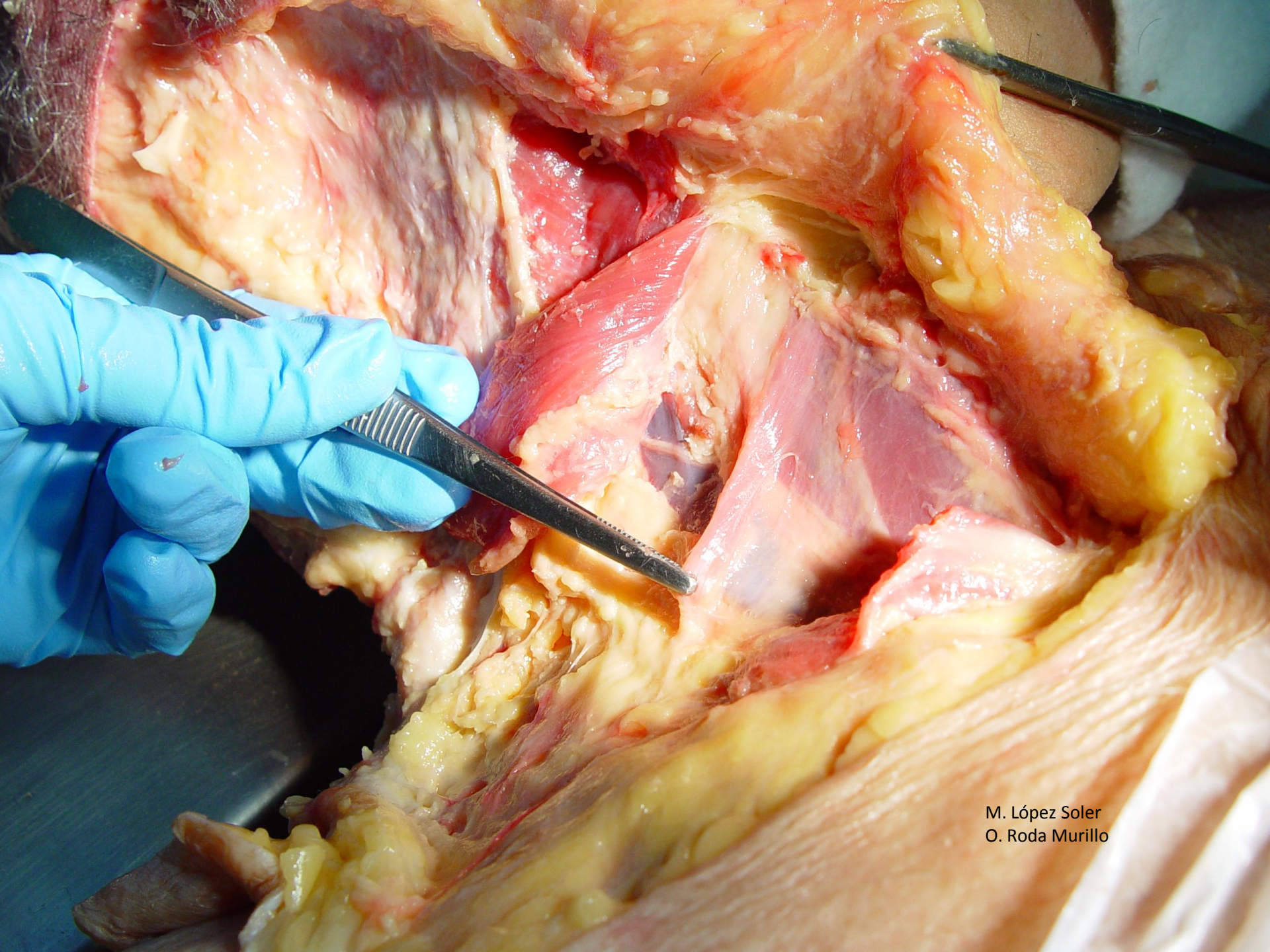
M. López Soler  
O. Roda Murillo



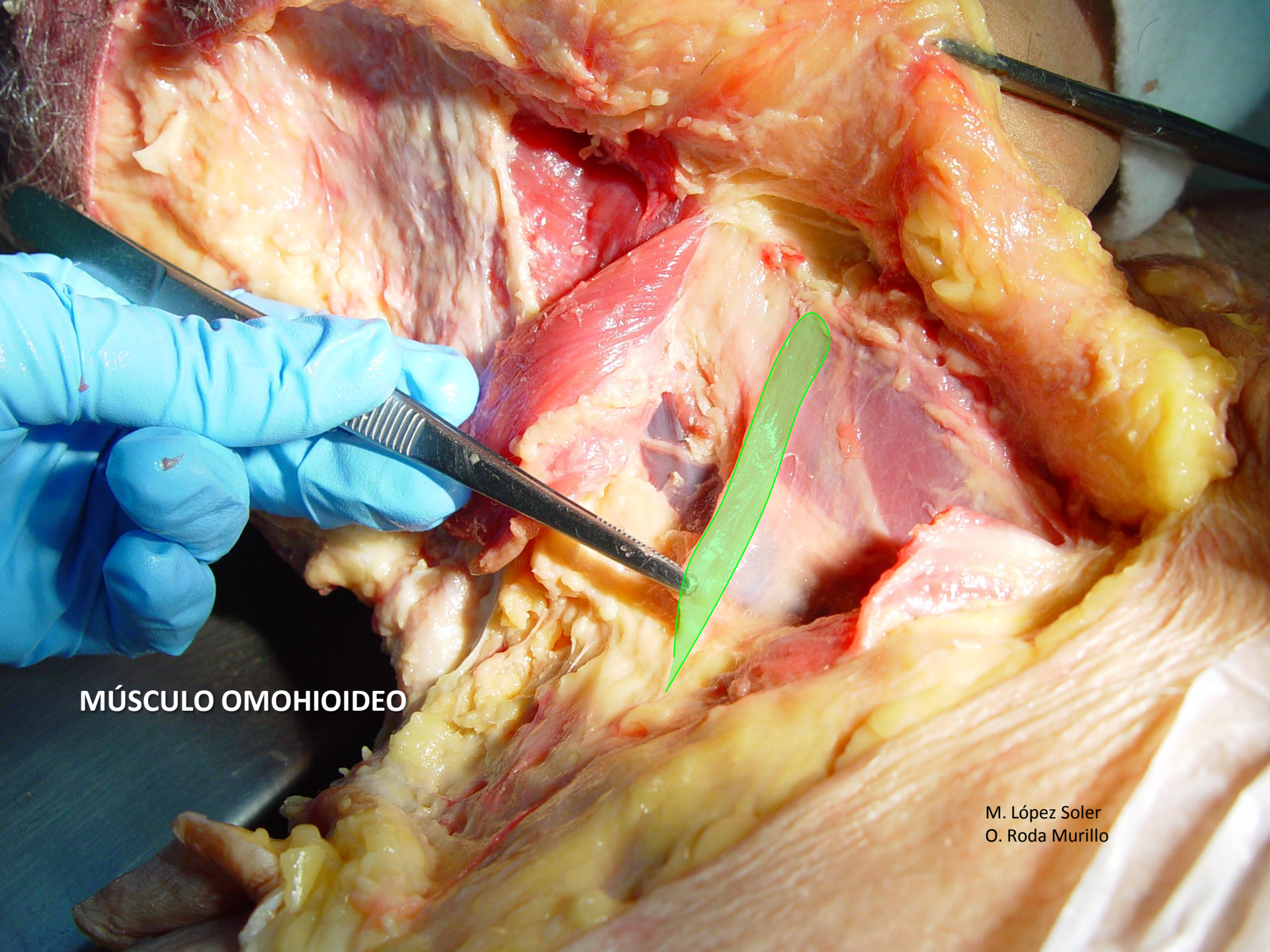
M. López Soler  
O. Roda Murillo



M. López Soler  
O. Roda Murillo



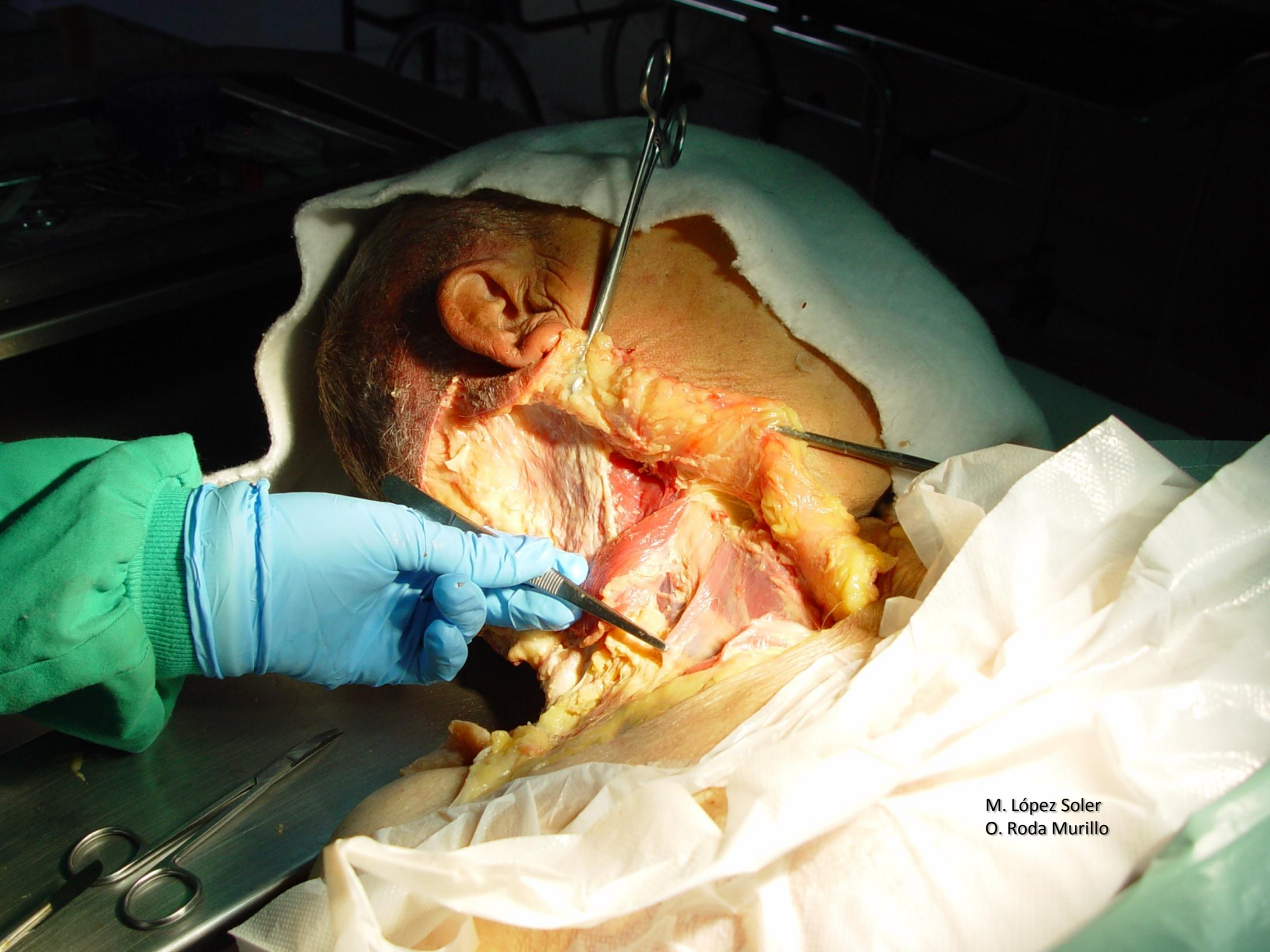M. López Soler  
O. Roda Murillo



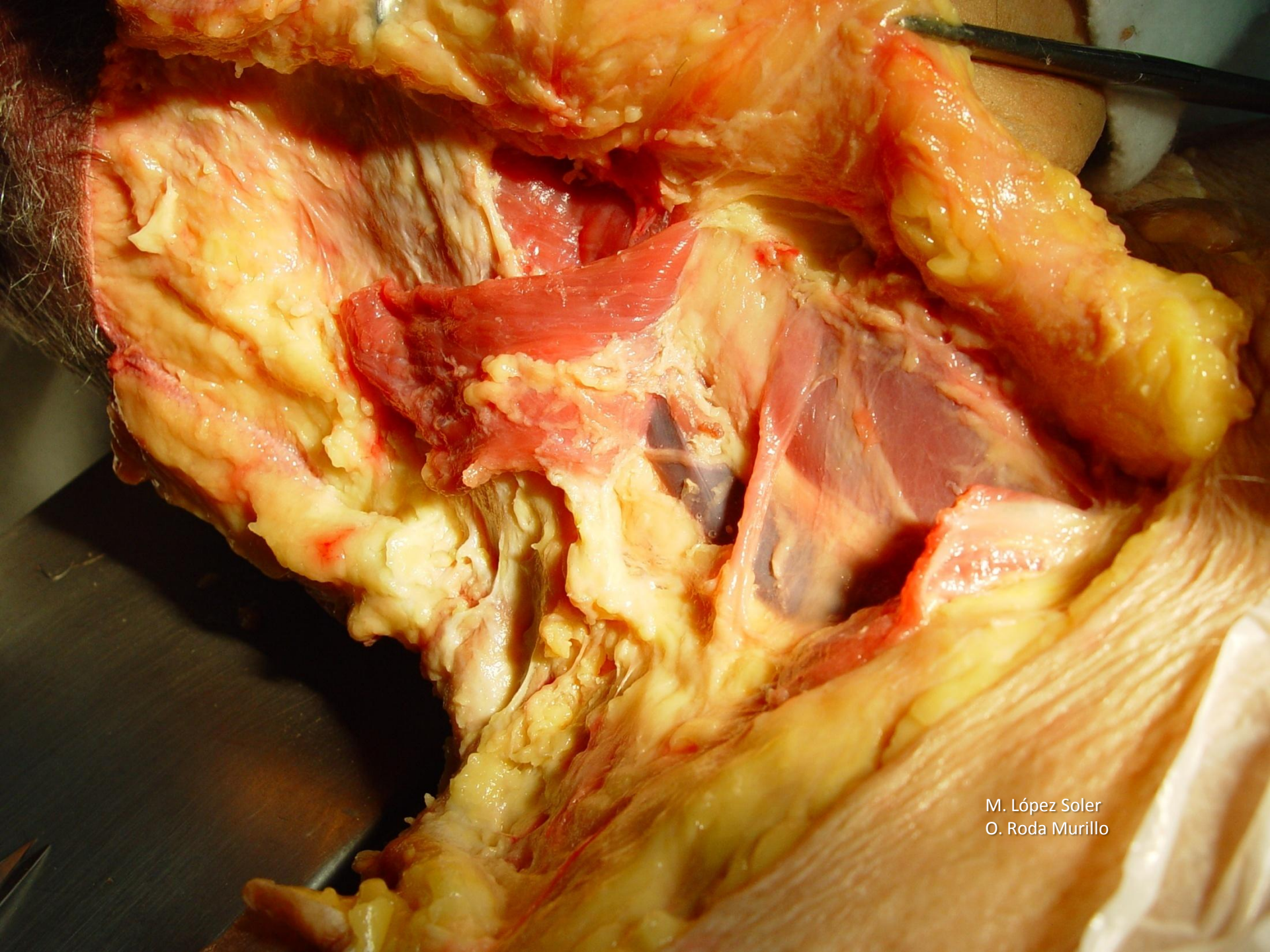
**MÚSCULO OMOHIOIDEO**

M. López Soler  
O. Roda Murillo

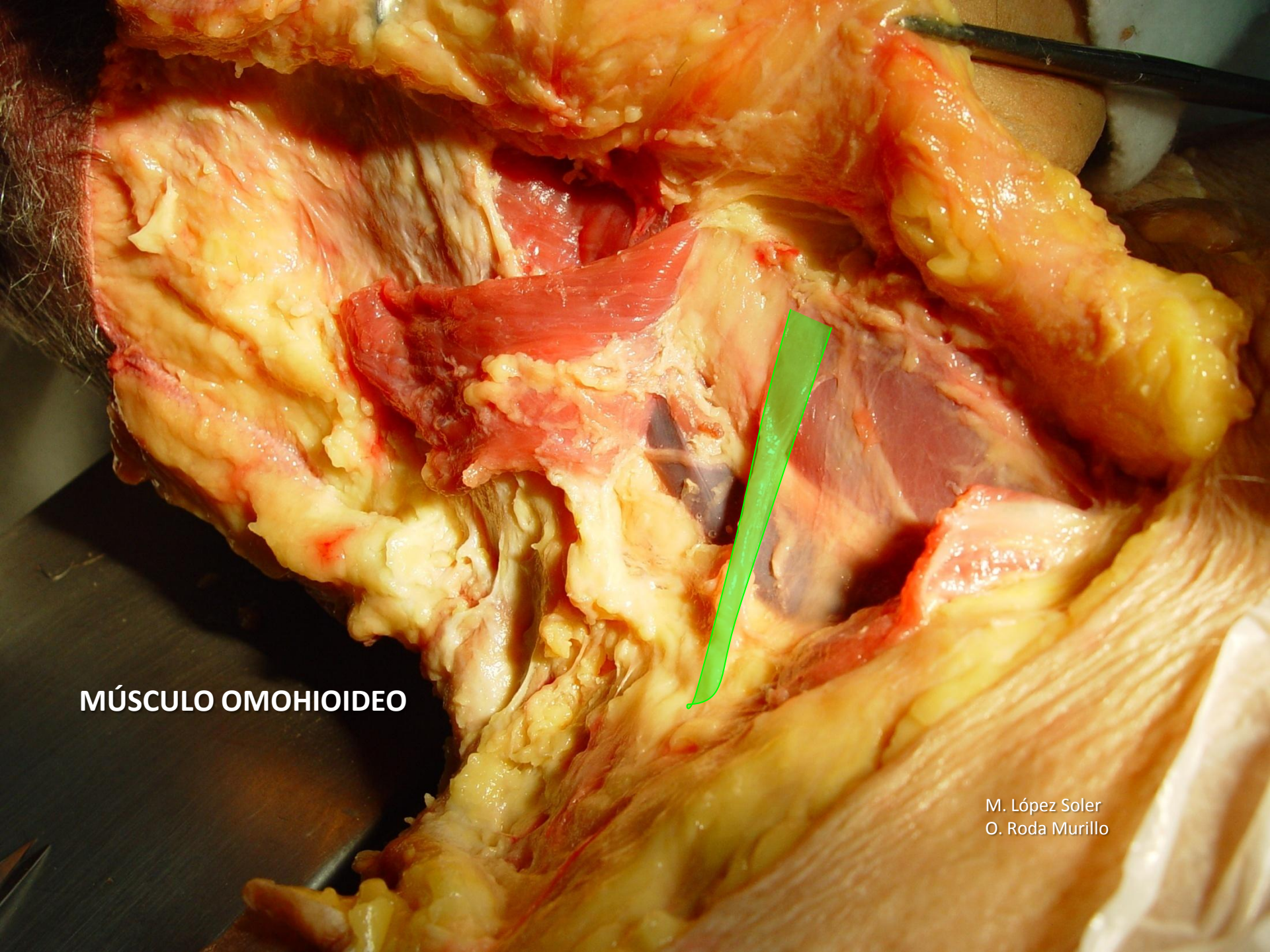




M. López Soler  
O. Roda Murillo

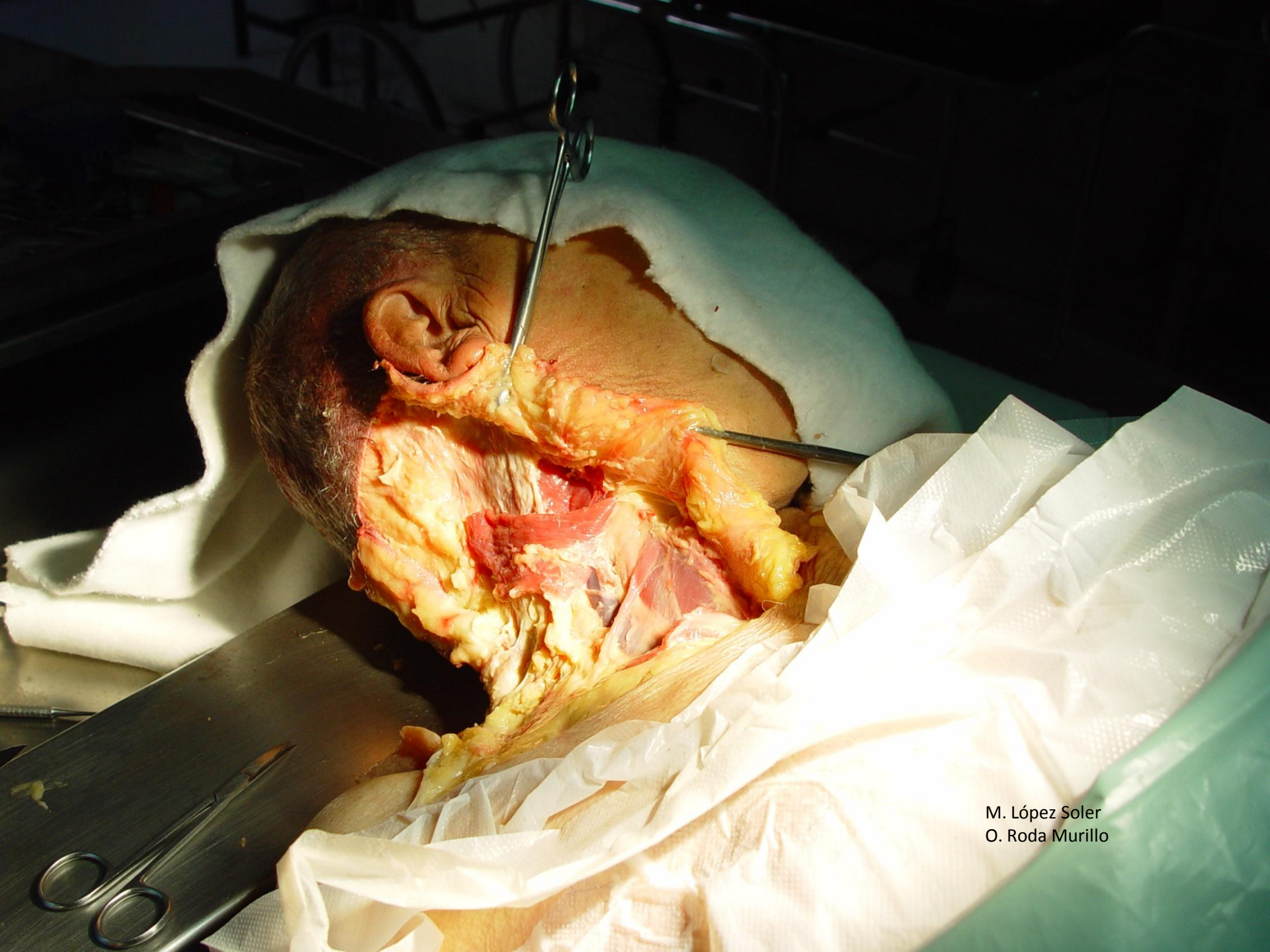


M. López Soler  
O. Roda Murillo

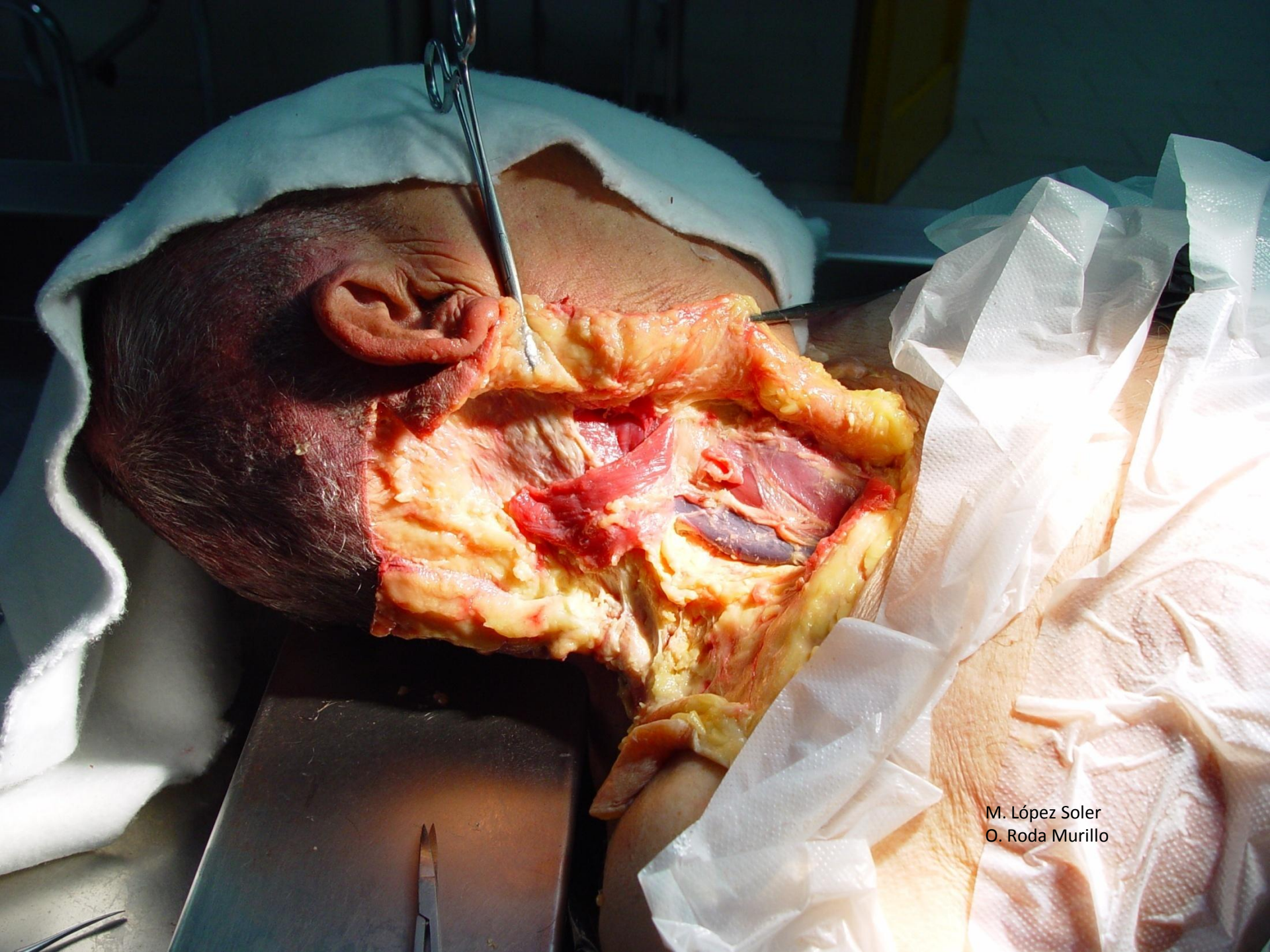

**MÚSCULO OMOHIOIDEO**

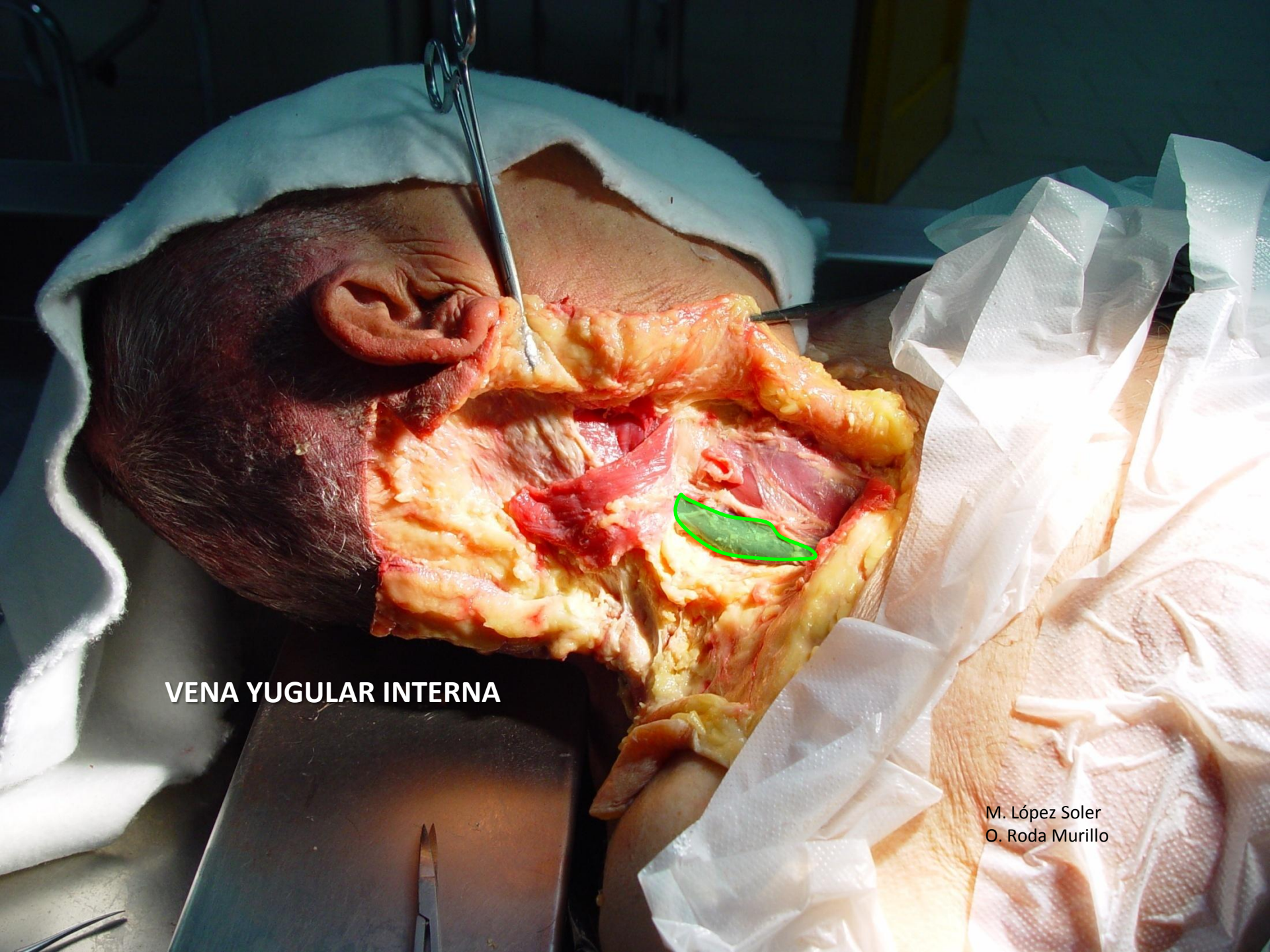M. López Soler  
O. Roda Murillo



M. López Soler  
O. Roda Murillo

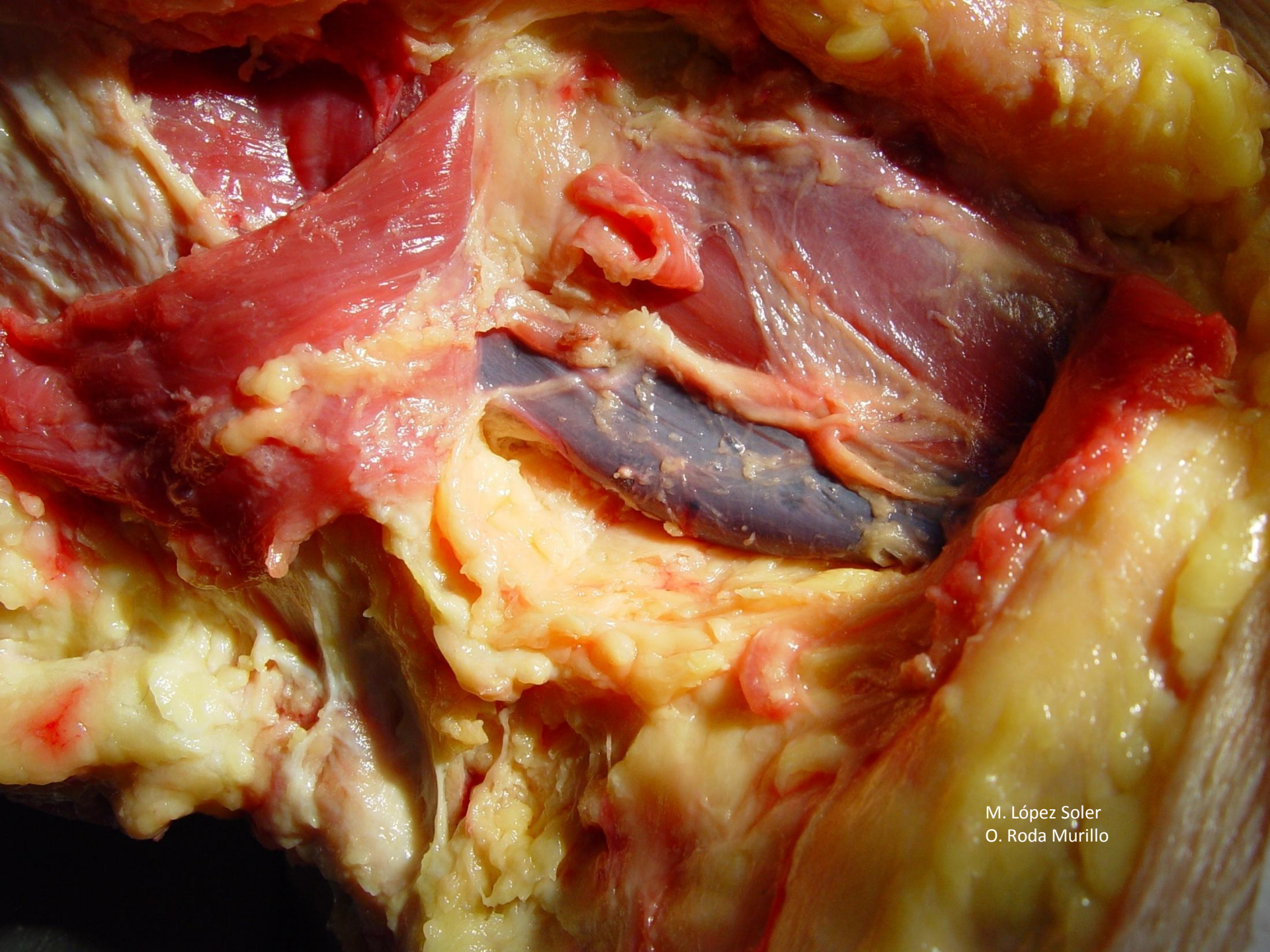


M. López Soler  
O. Roda Murillo

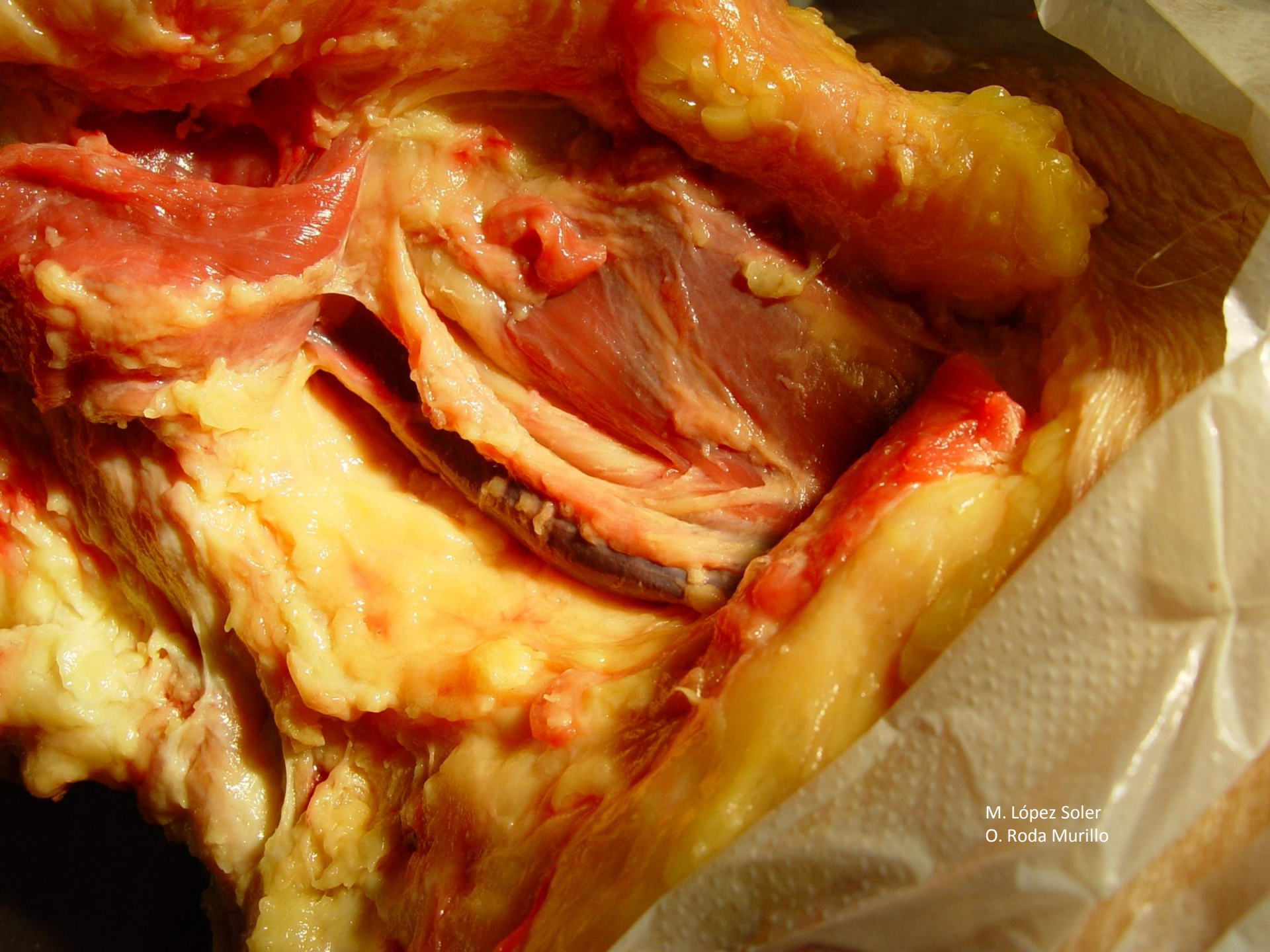


**VENA YUGULAR INTERNA**

M. López Soler  
O. Roda Murillo

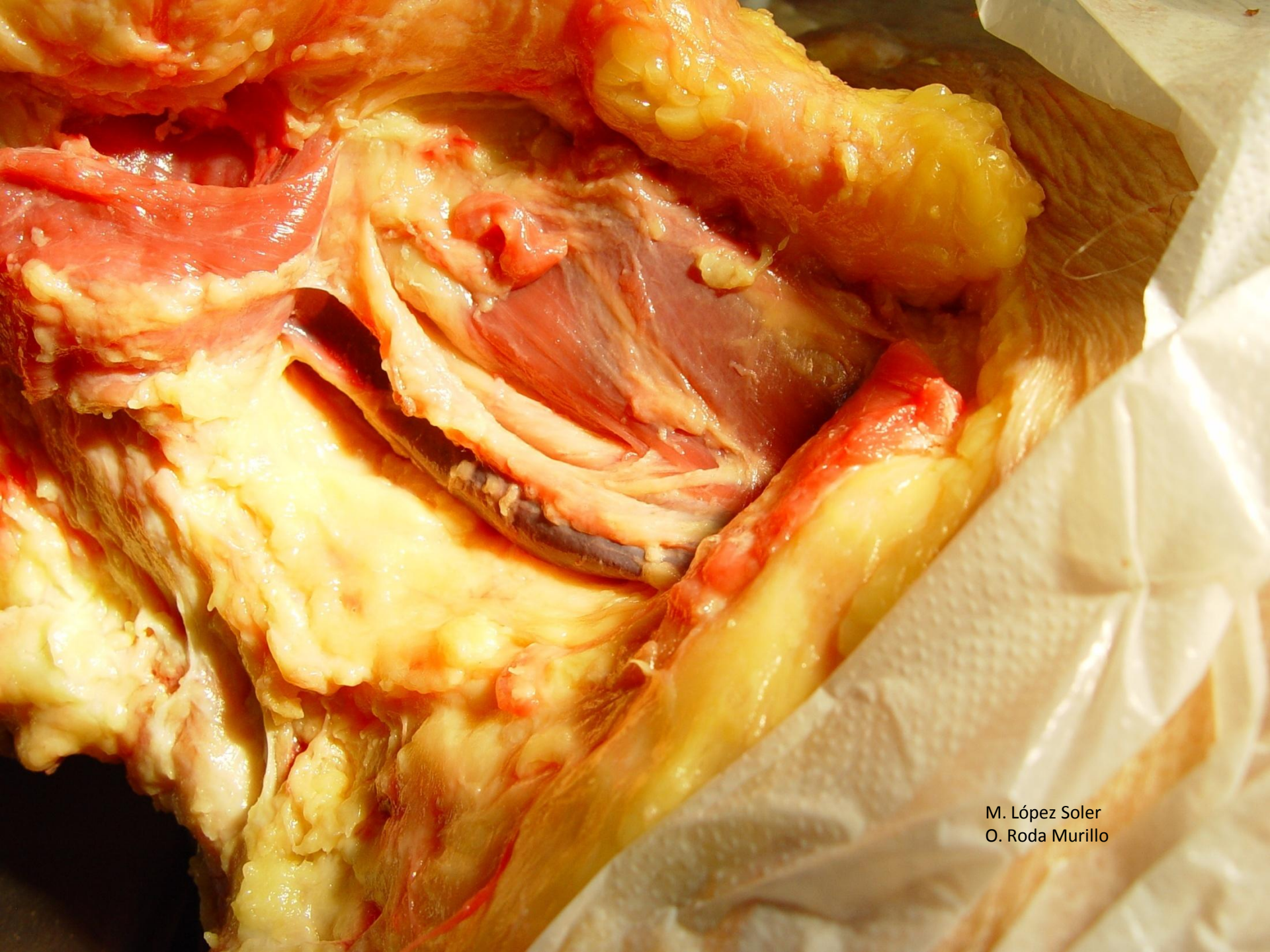


M. López Soler  
O. Roda Murillo

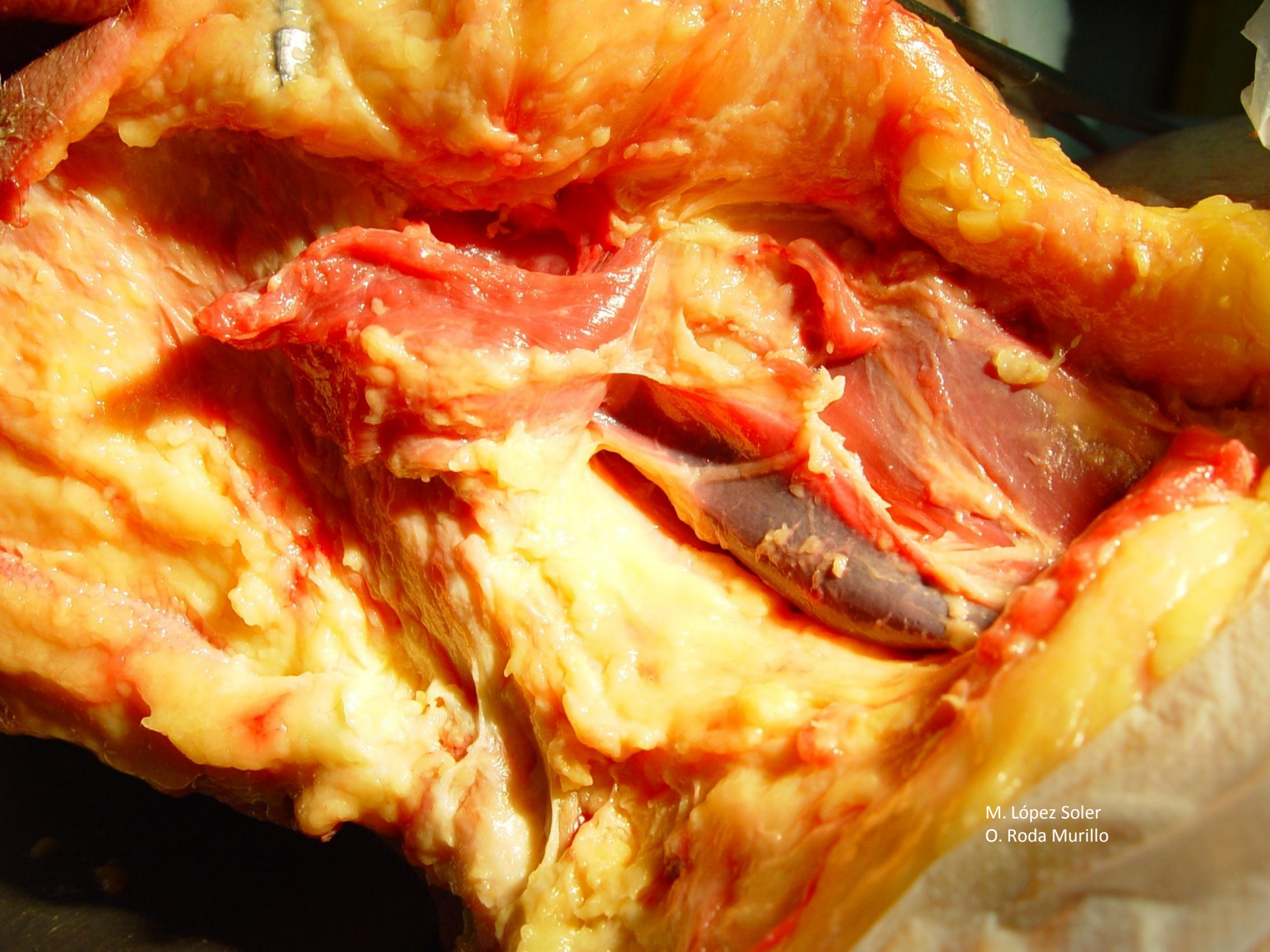

M. López Soler  
O. Roda Murillo

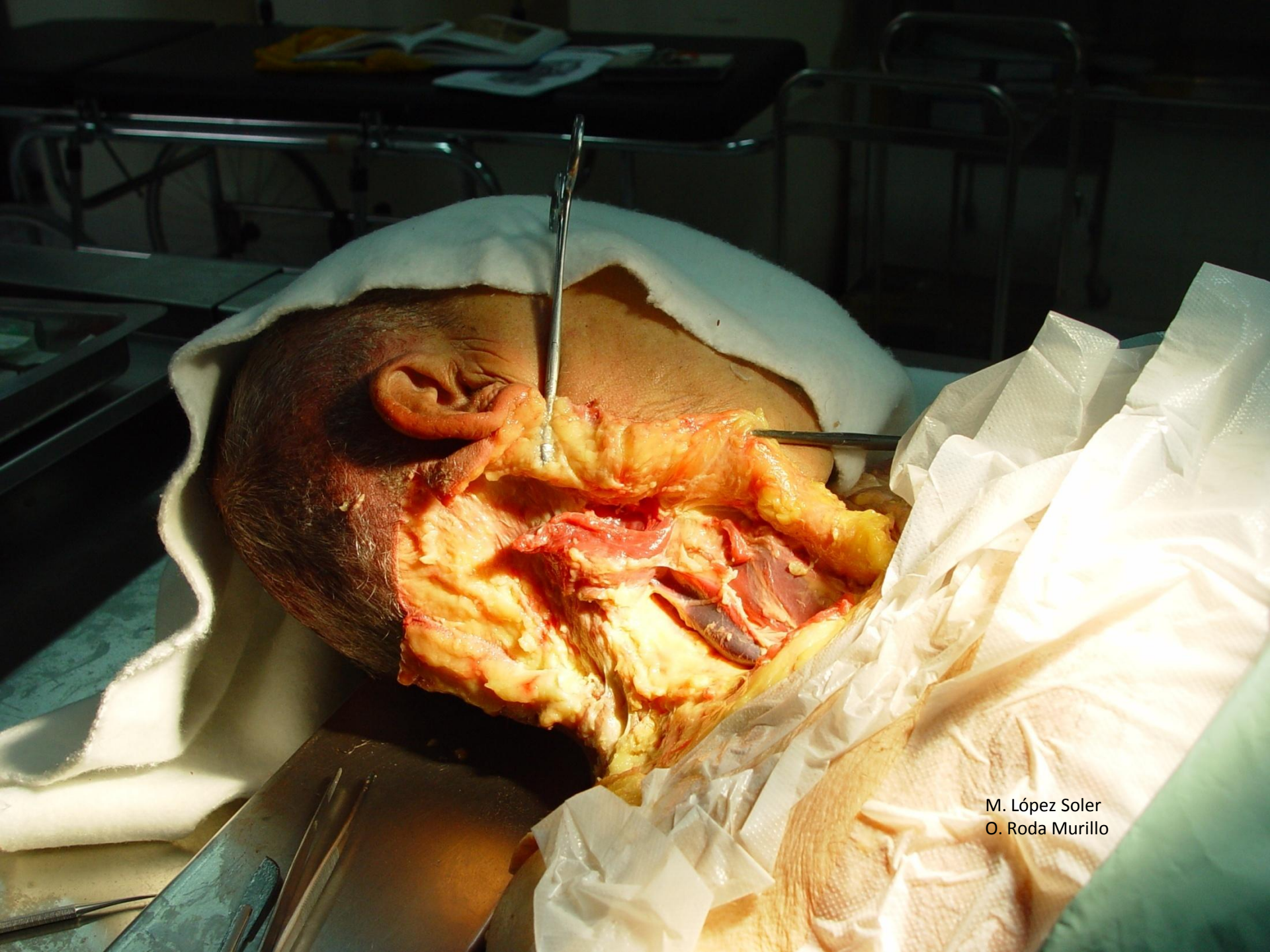



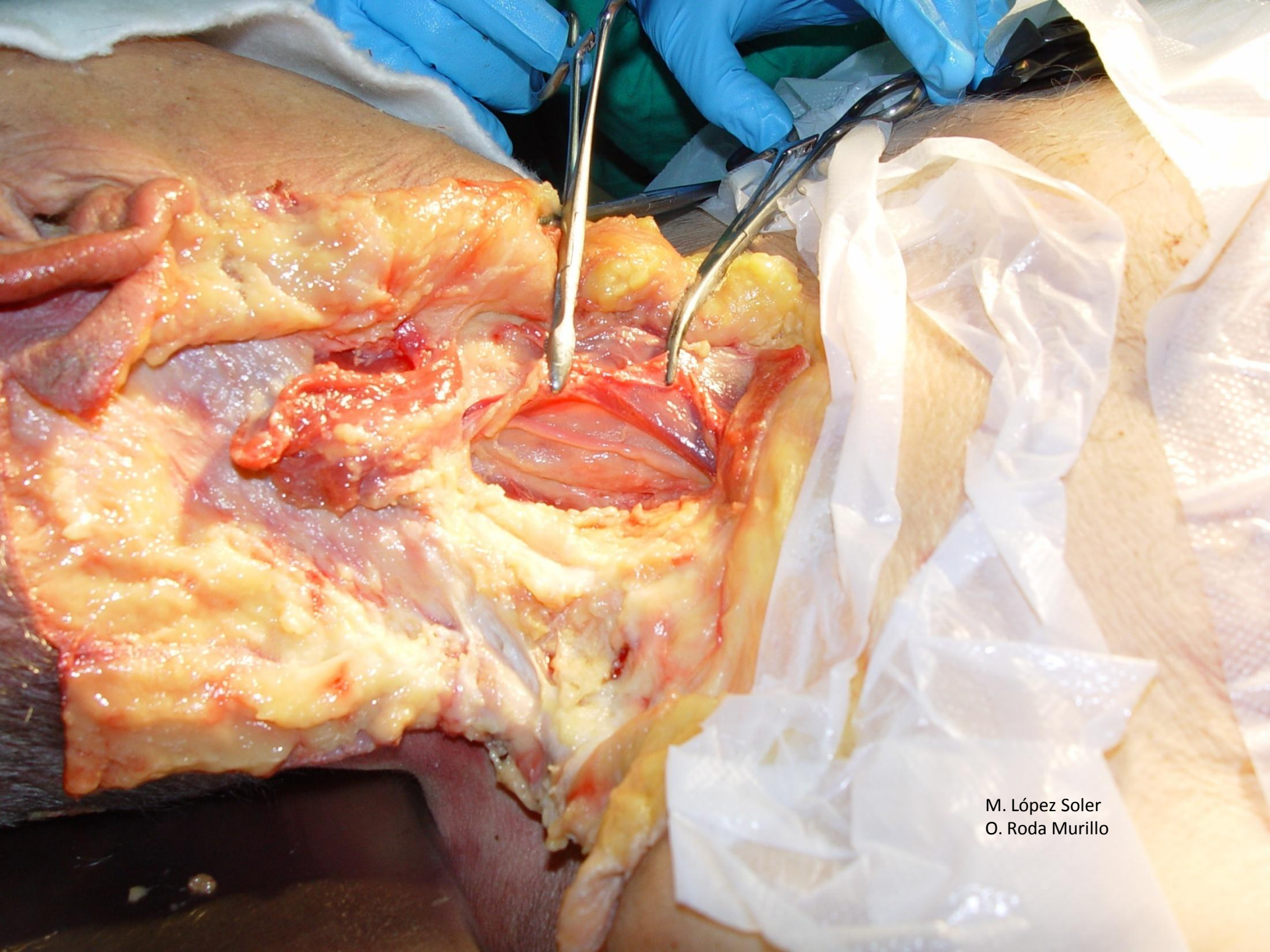
M. López Soler  
O. Roda Murillo



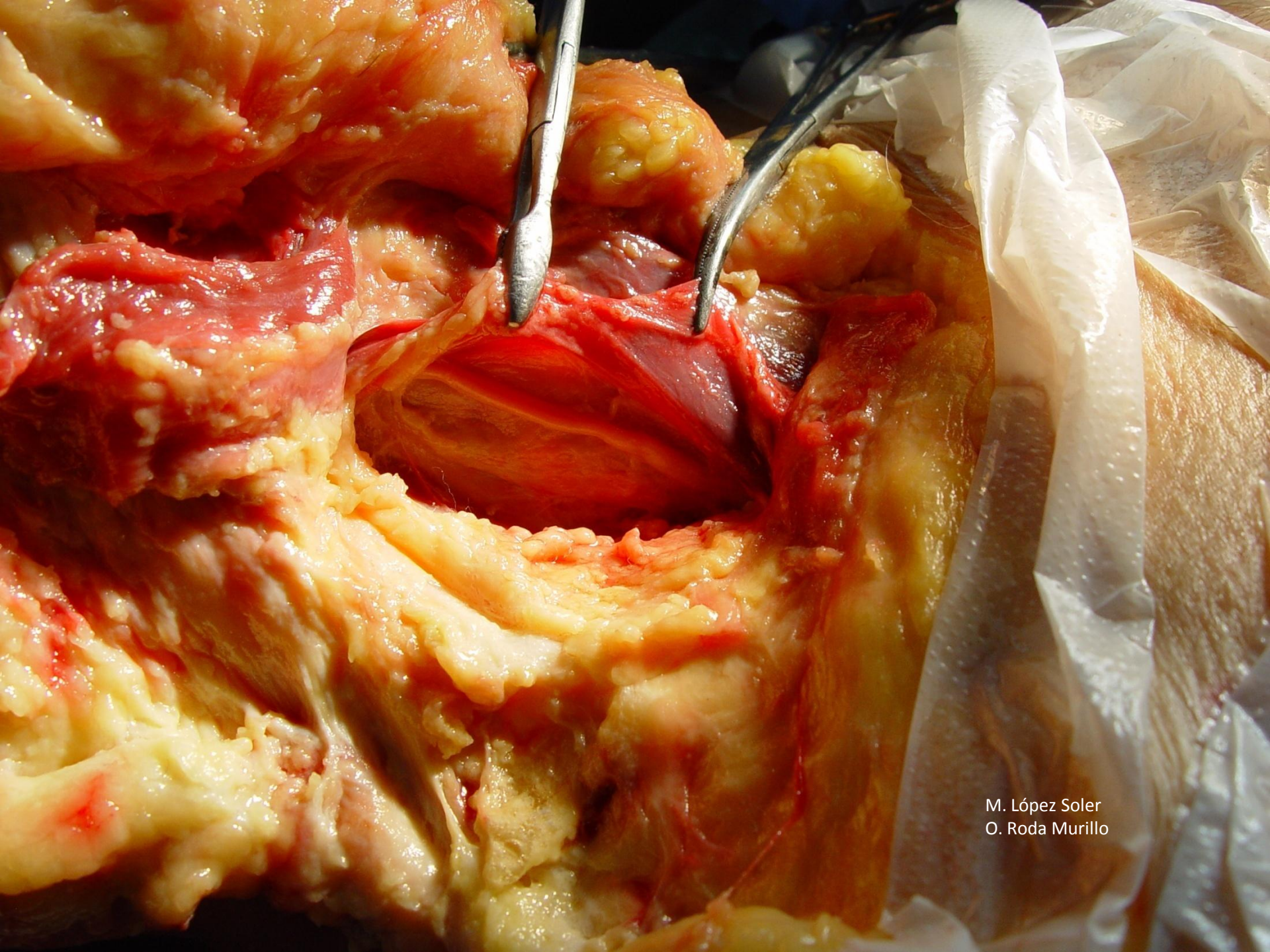M. López Soler  
O. Roda Murillo



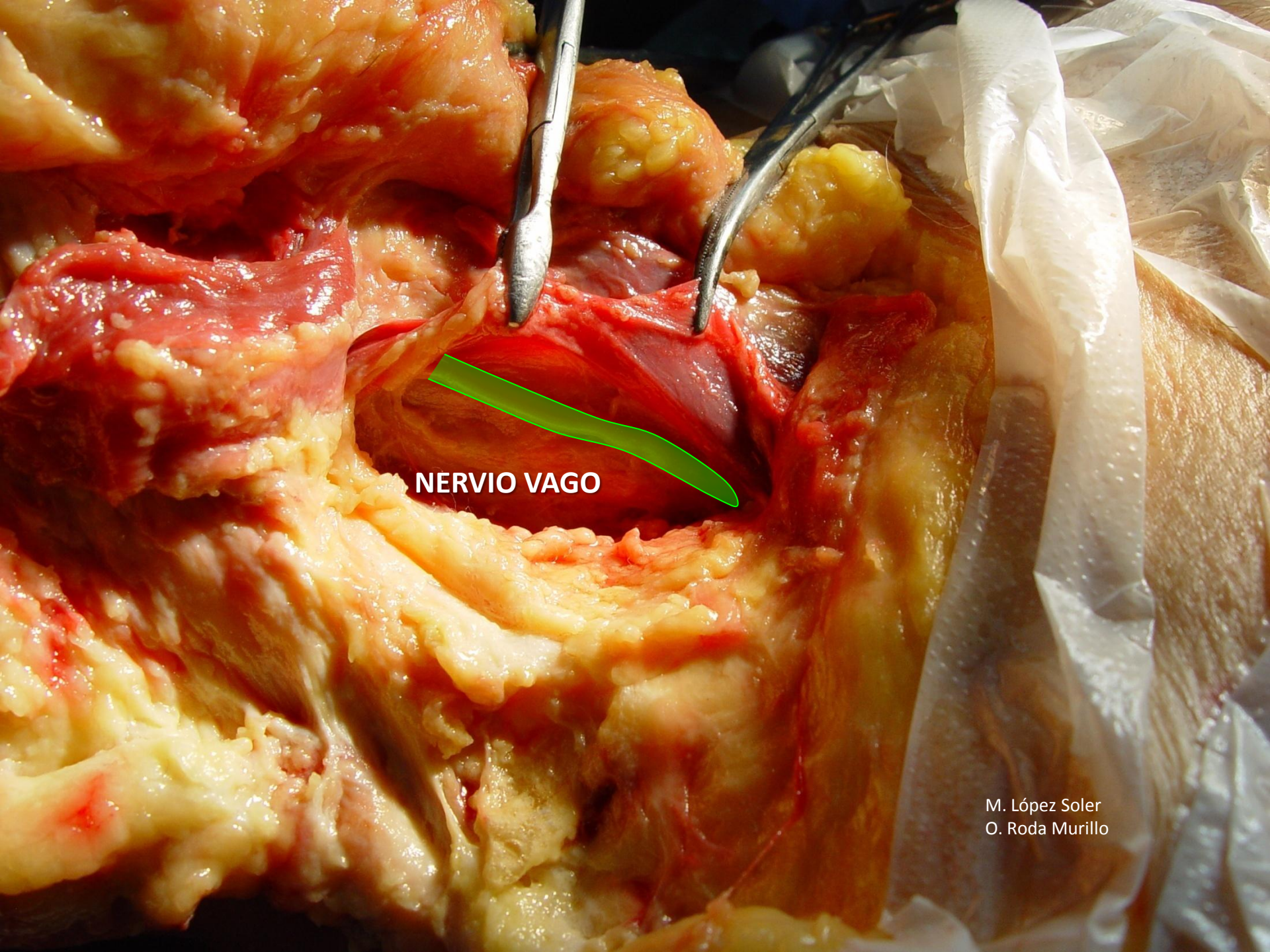M. López Soler  
O. Roda Murillo



M. López Soler  
O. Roda Murillo

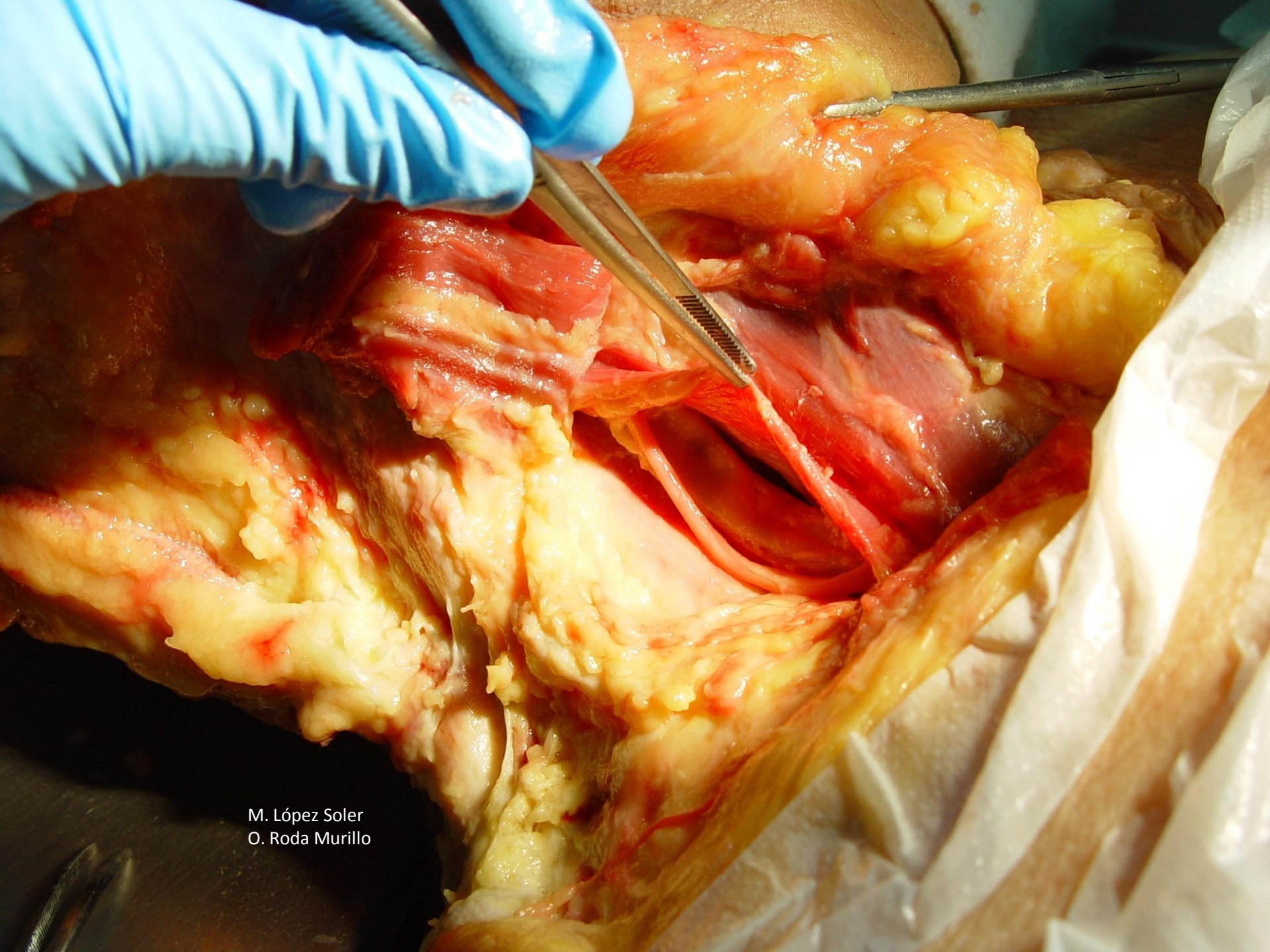


M. López Soler  
O. Roda Murillo

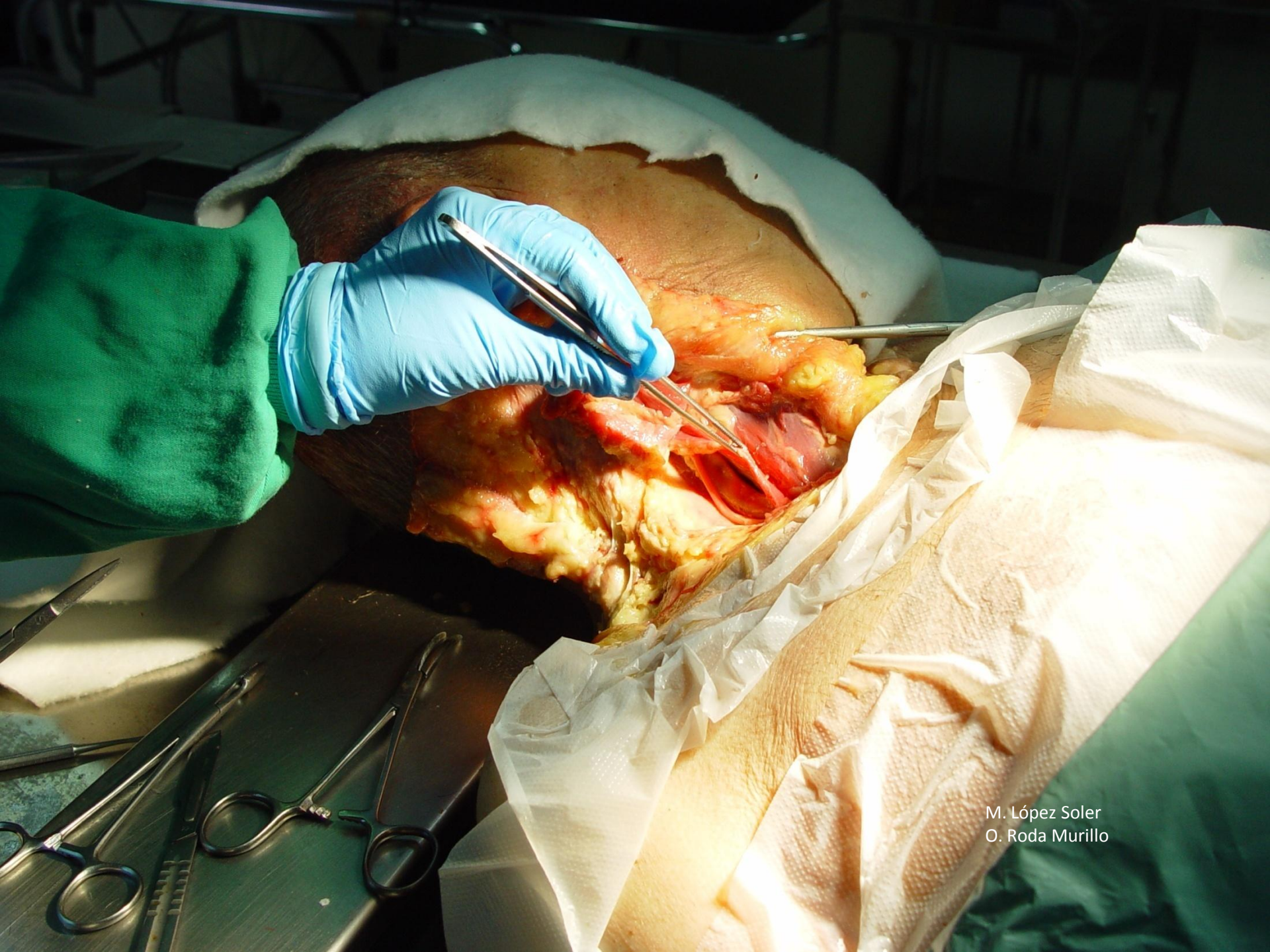

**NERVIO VAGO**

M. López Soler  
O. Roda Murillo

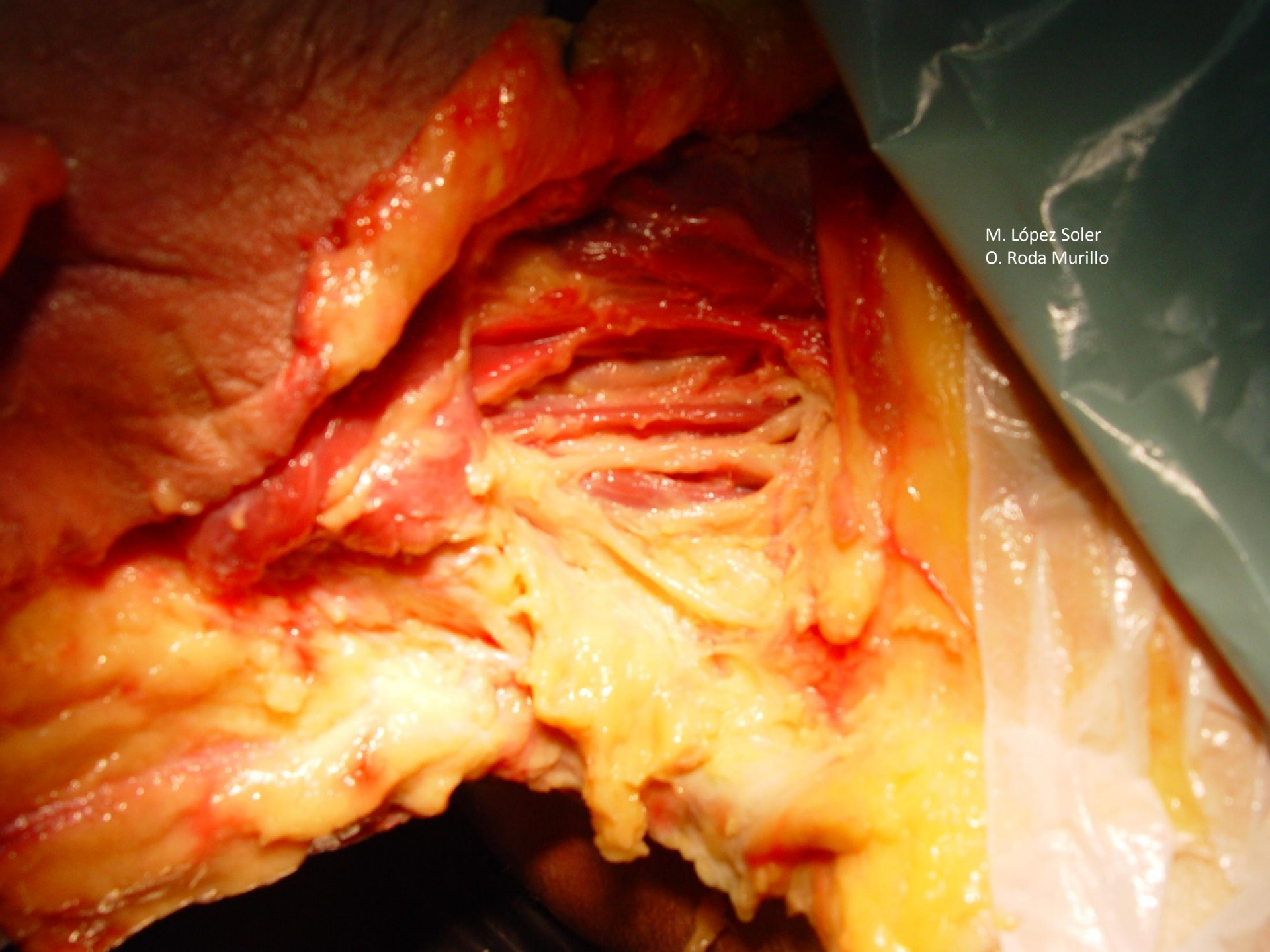


M. López Soler  
O. Roda Murillo



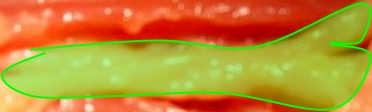
M. López Soler  
O. Roda Murillo



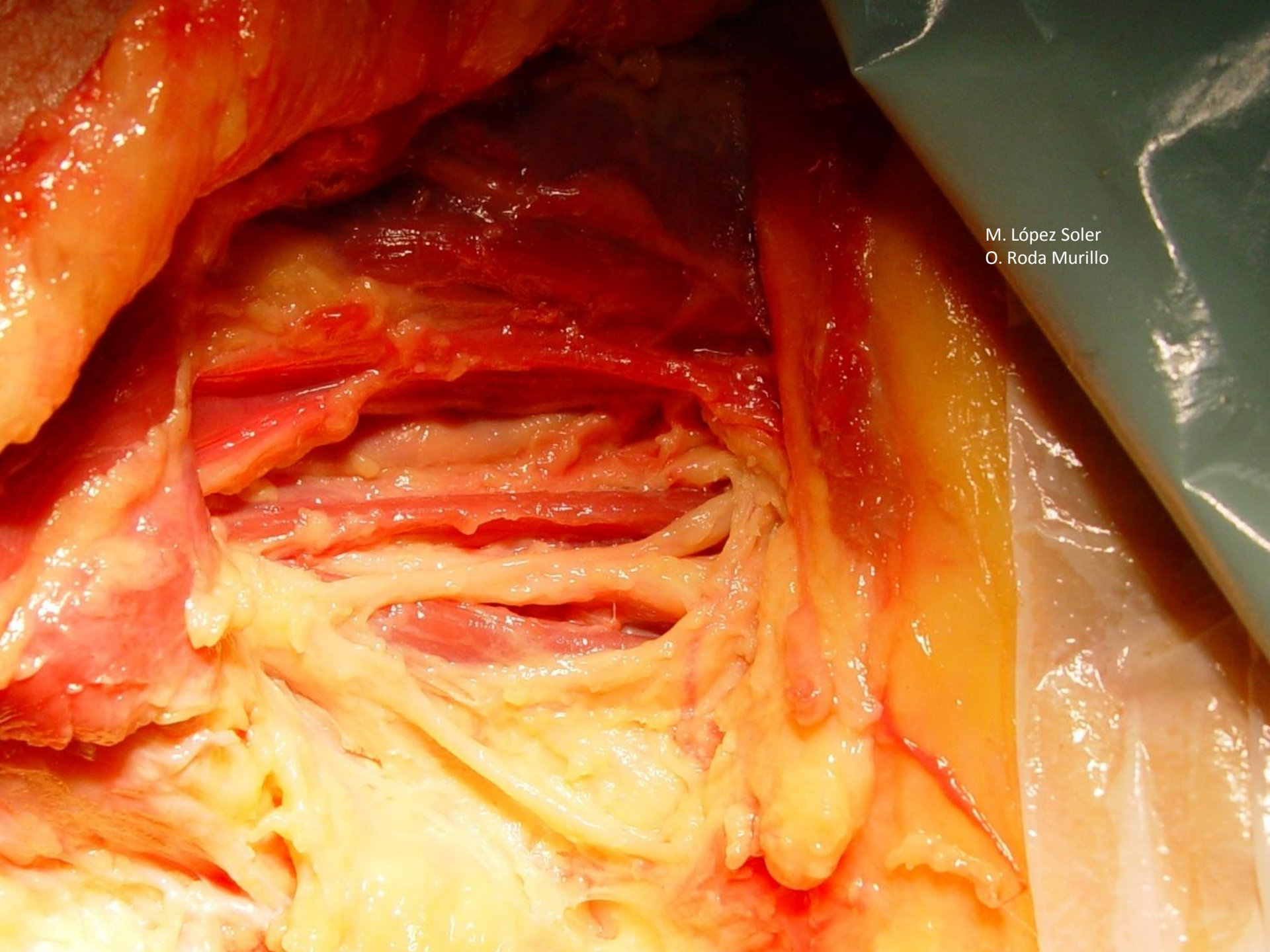


M. López Soler  
O. Roda Murillo

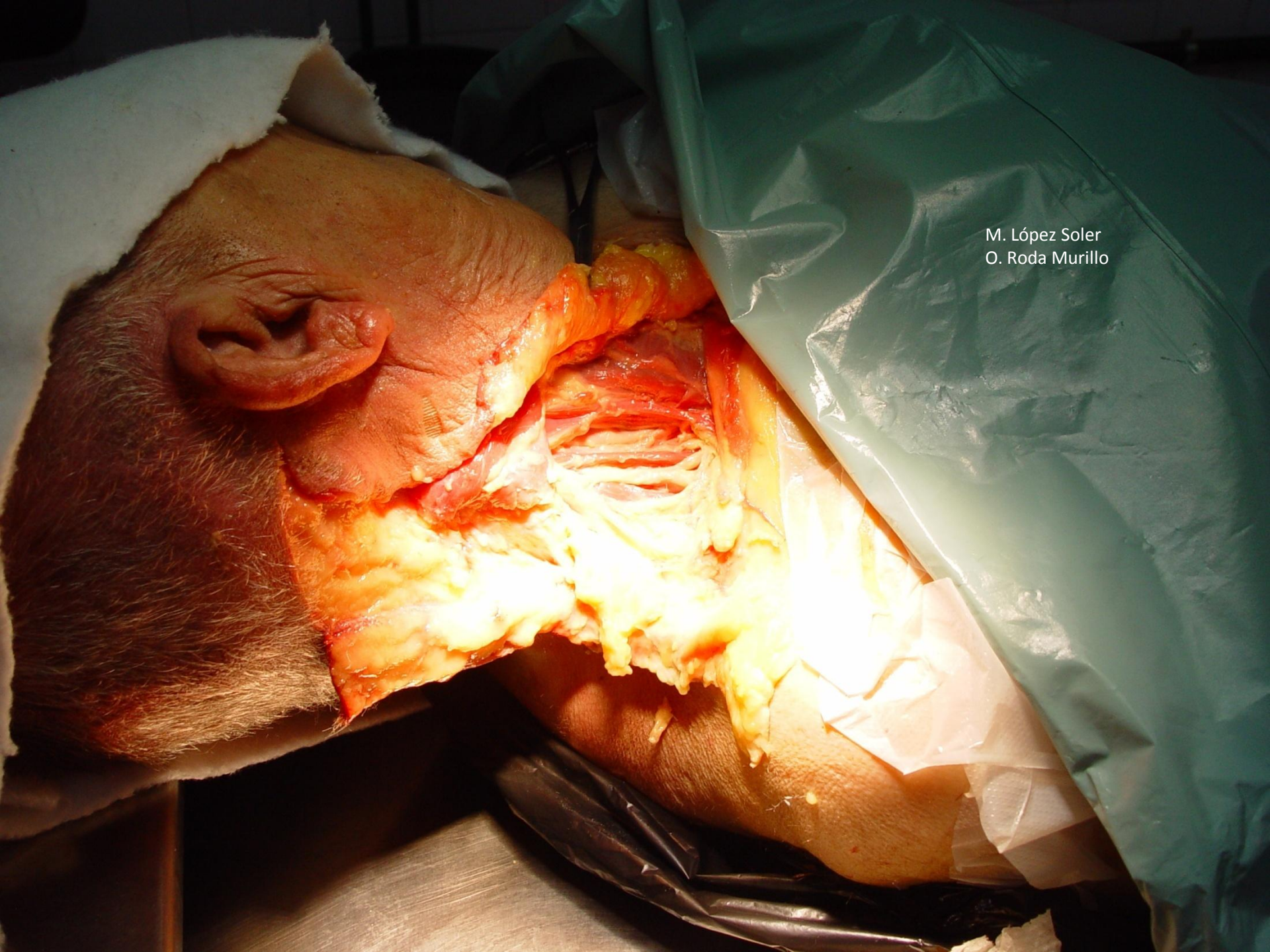
M. López Soler  
O. Roda Murillo



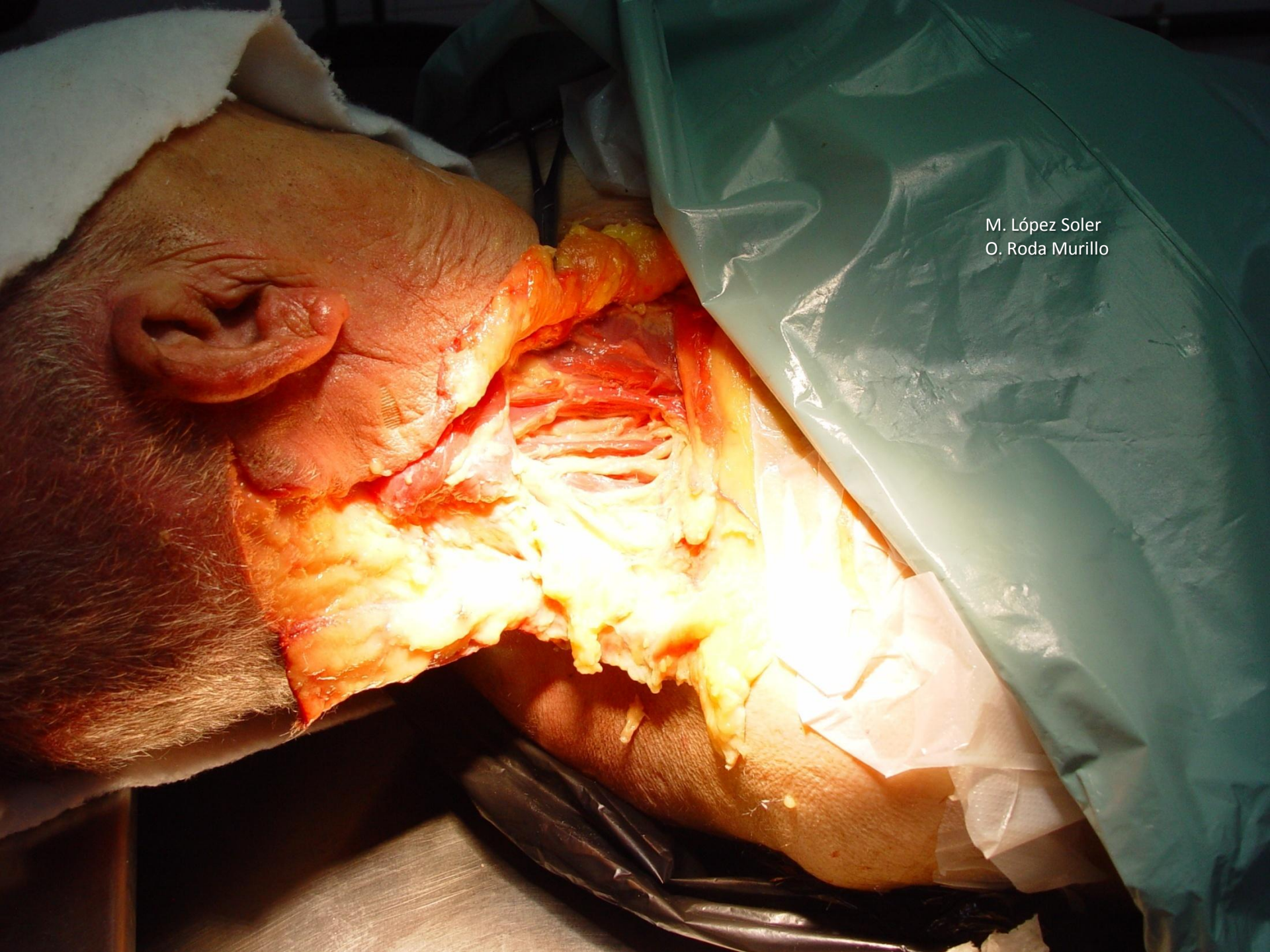
**NERVIO VAGO**



M. López Soler  
O. Roda Murillo



M. López Soler  
O. Roda Murillo

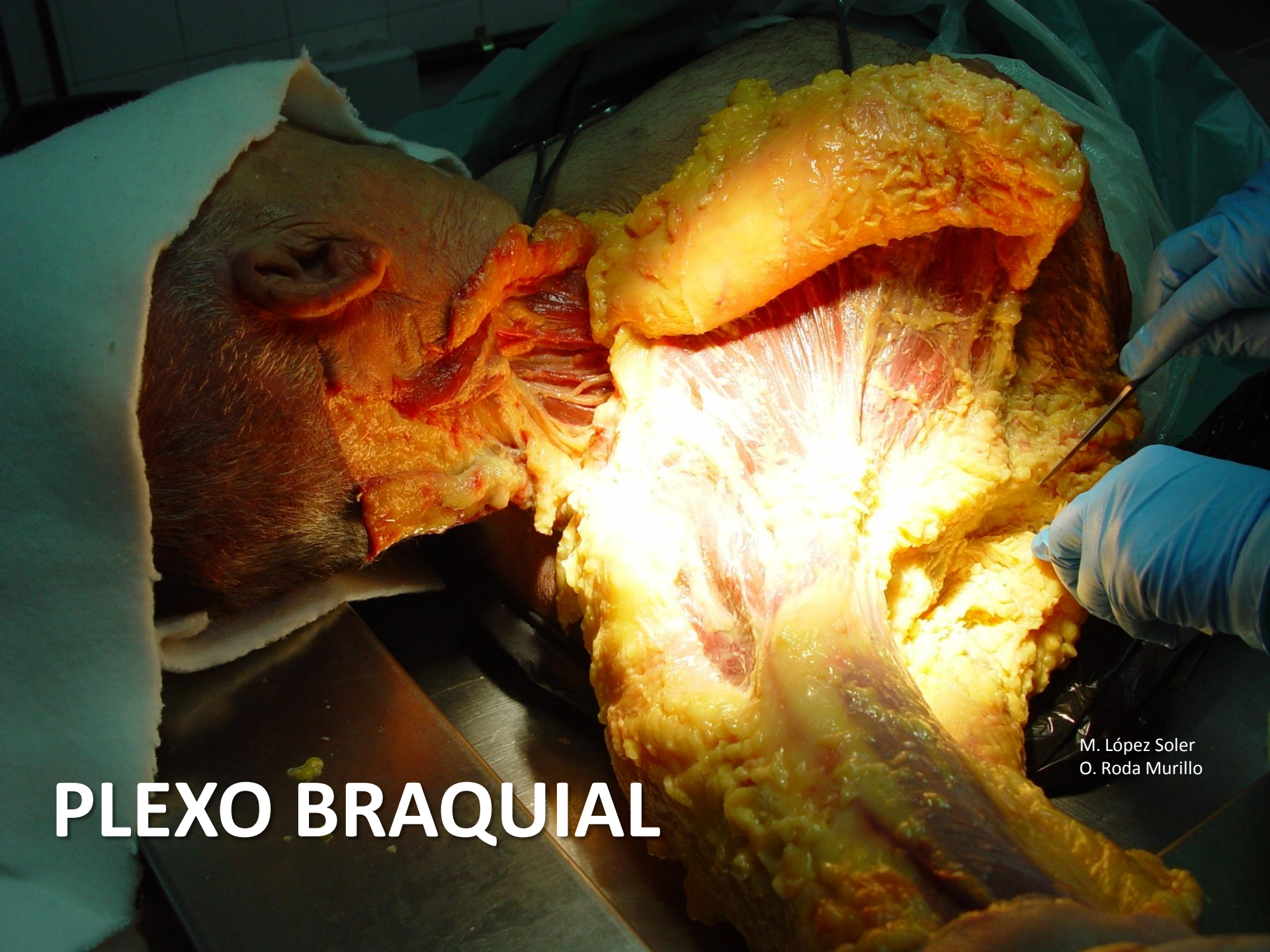


M. López Soler  
O. Roda Murillo

M. López Soler  
O. Roda Murillo

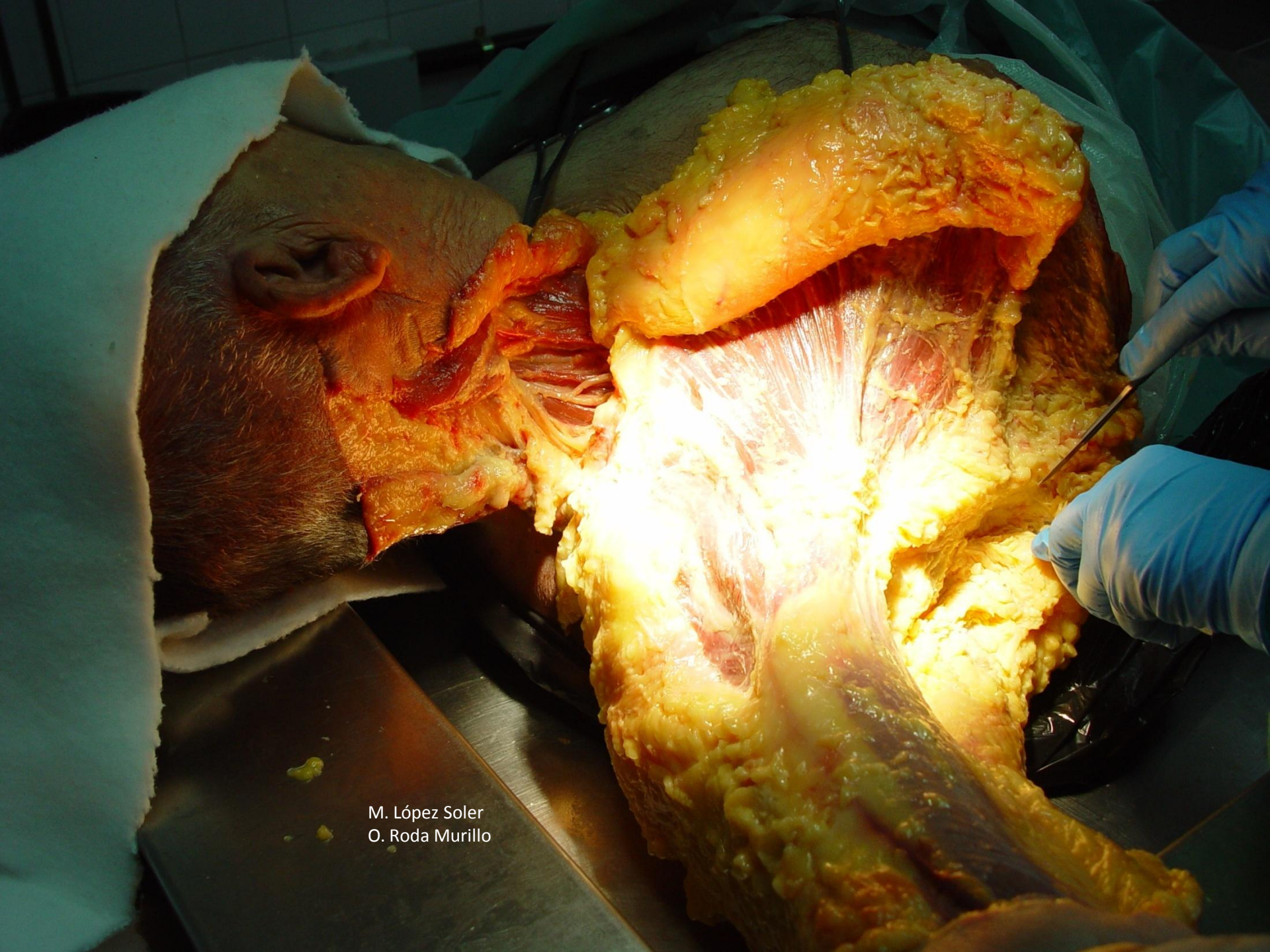


**NERVIO VAGO**



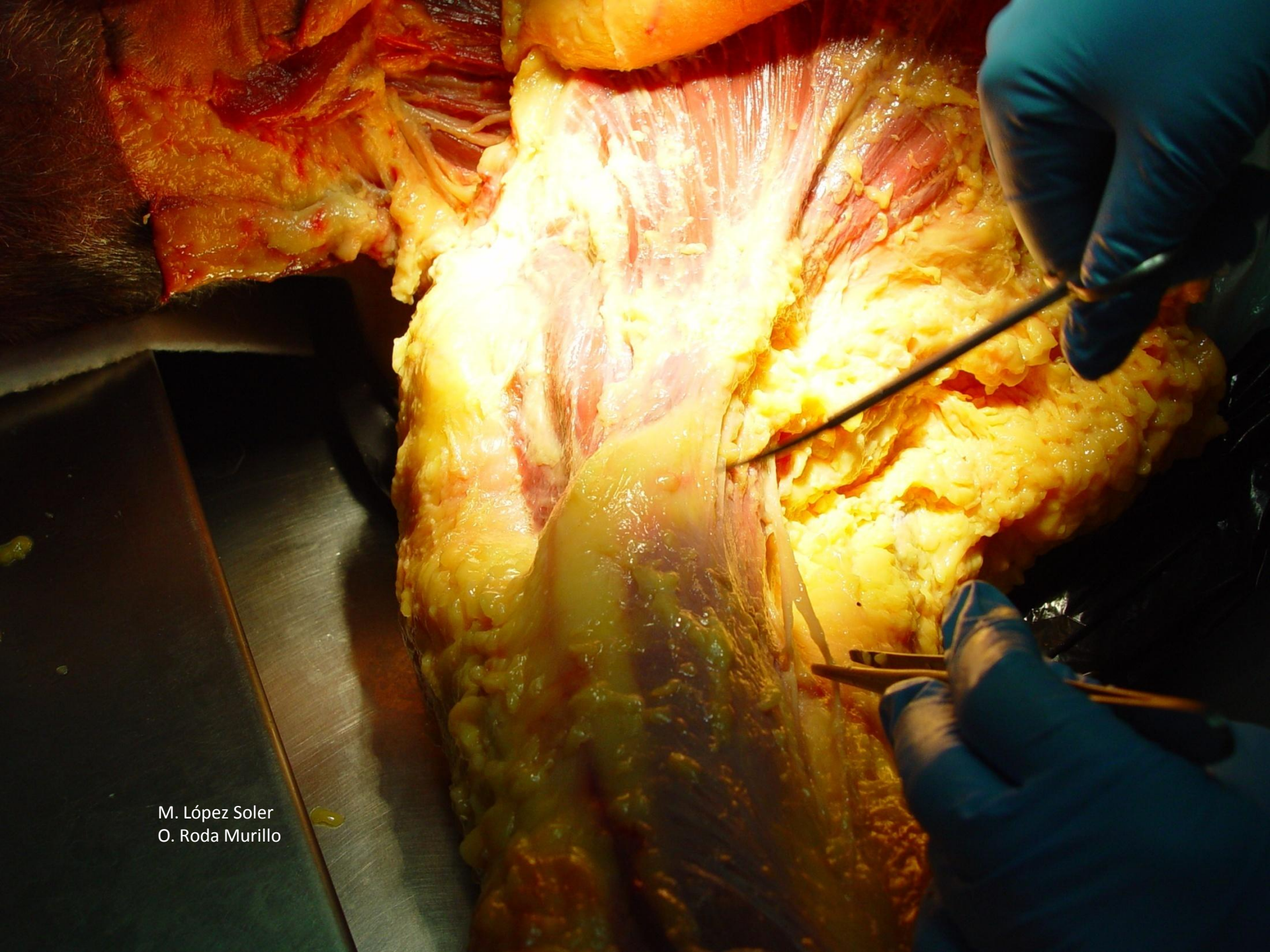
# PLEXO BRAQUIAL

M. López Soler  
O. Roda Murillo

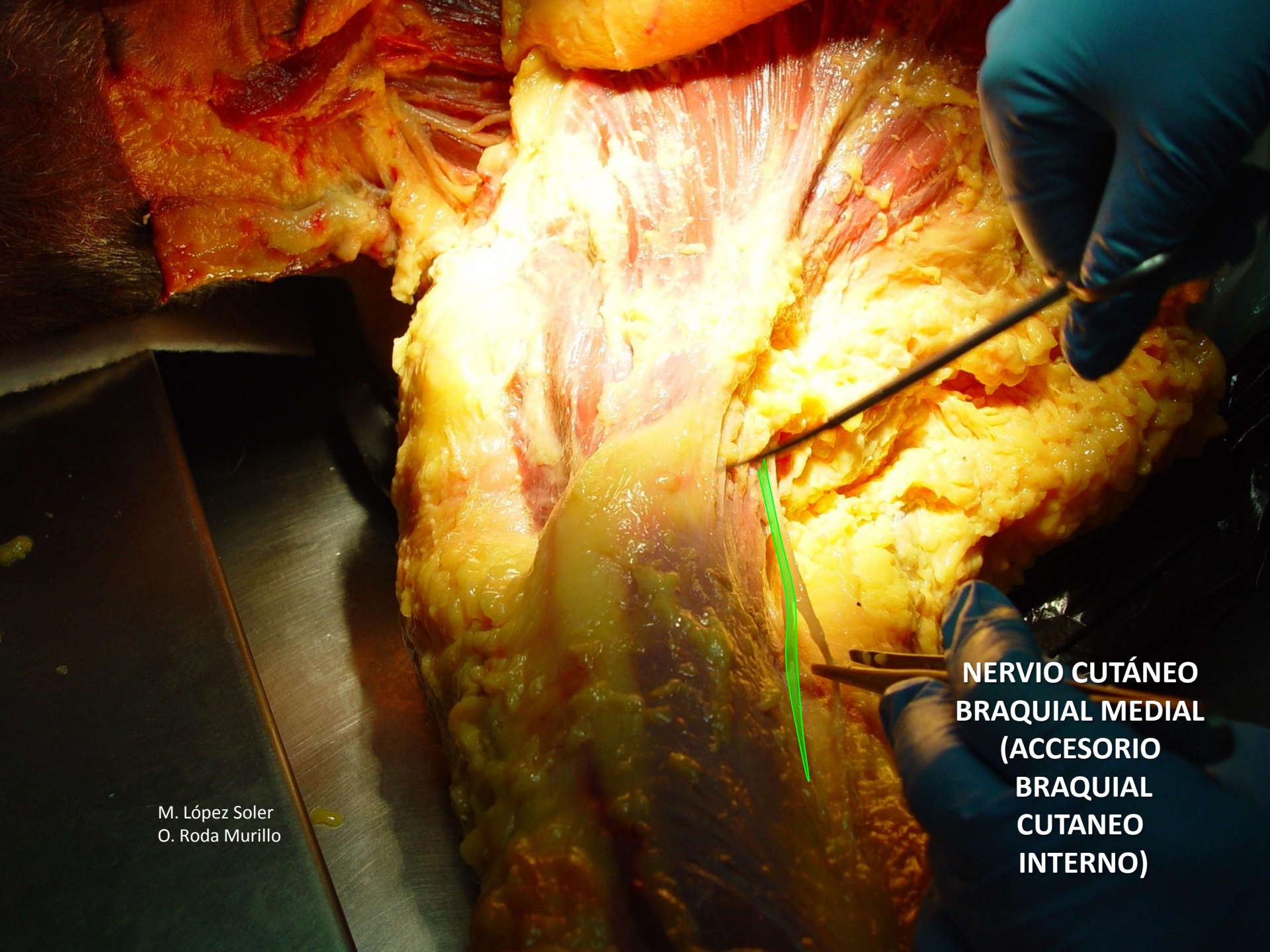


M. López Soler  
O. Roda Murillo



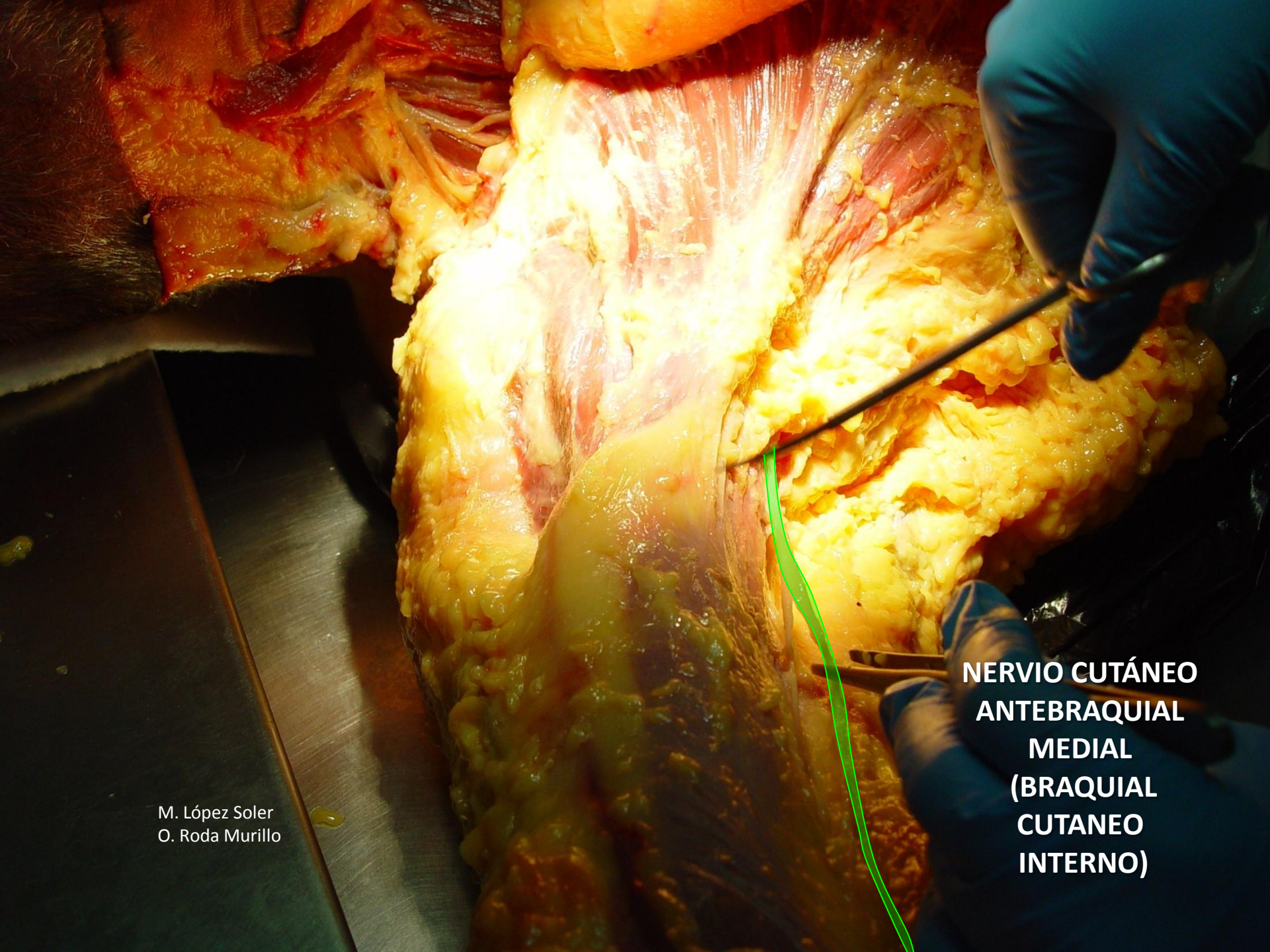


M. López Soler  
O. Roda Murillo



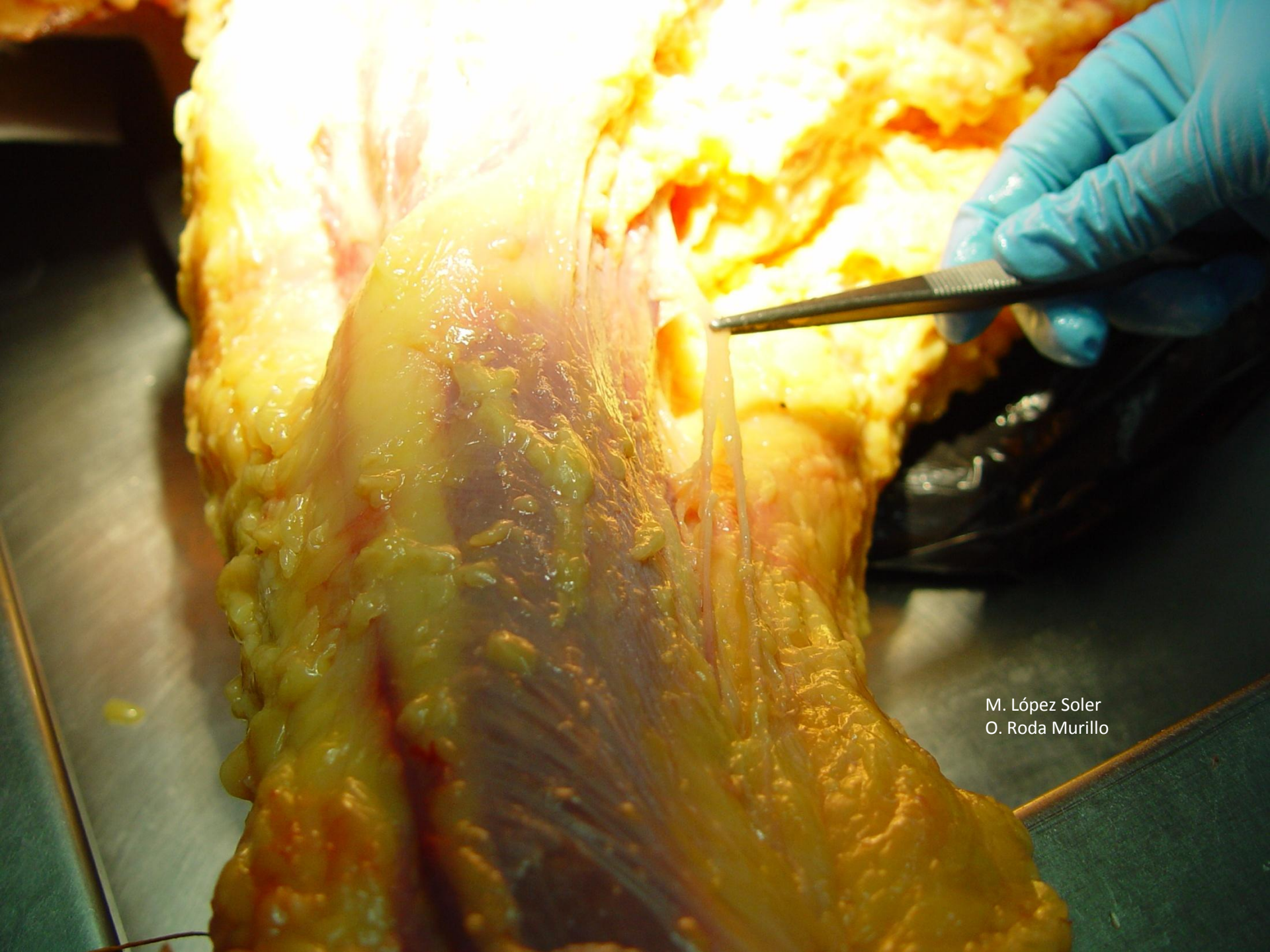
**NERVIO CUTÁNEO  
BRAQUIAL MEDIAL  
(ACCESORIO  
BRAQUIAL  
CUTANEO  
INTERNO)**

M. López Soler  
O. Roda Murillo

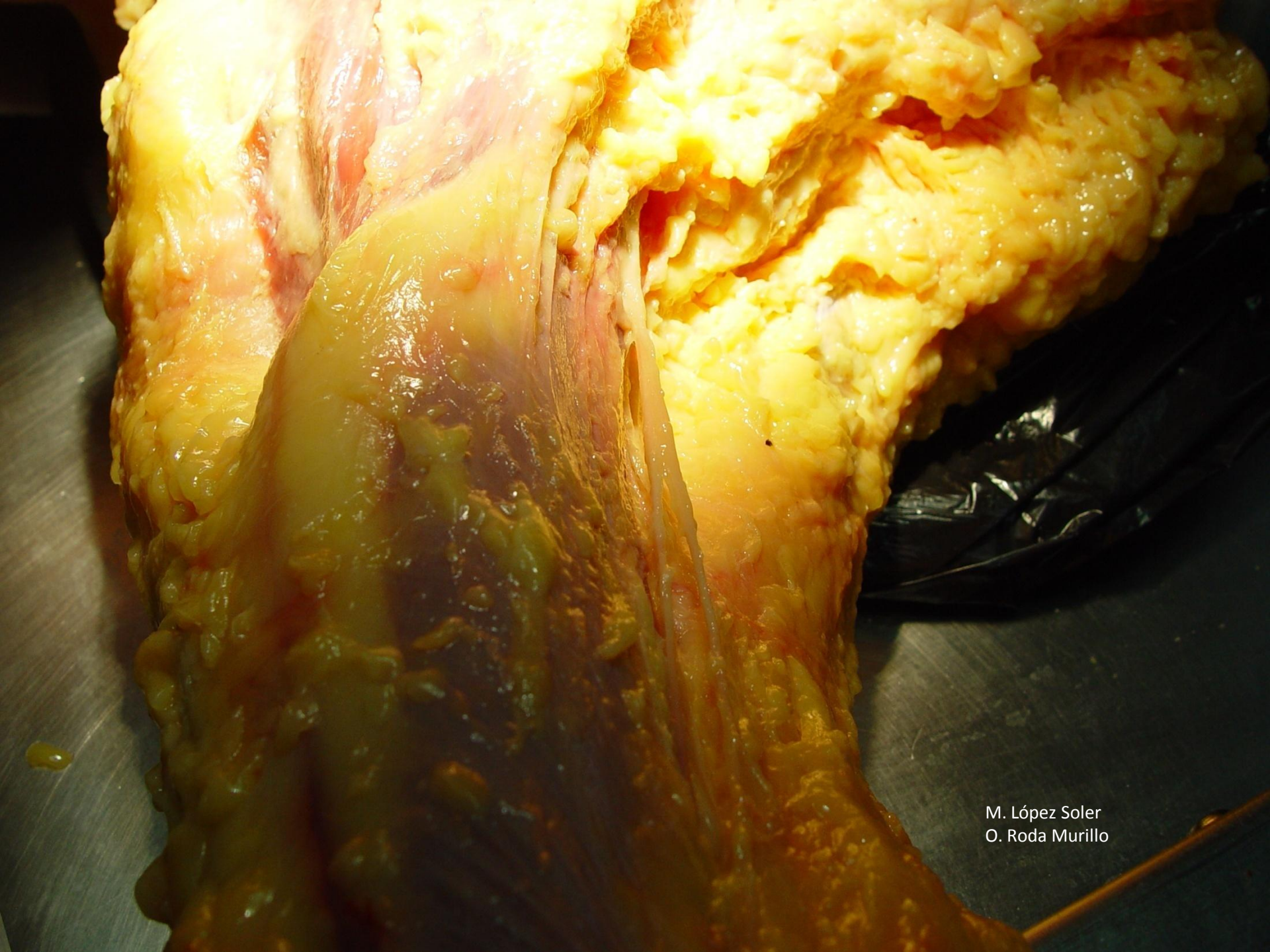


**NERVIO CUTÁNEO  
ANTEBRAQUIAL  
MEDIAL  
(BRAQUIAL  
CUTANEO  
INTERNO)**

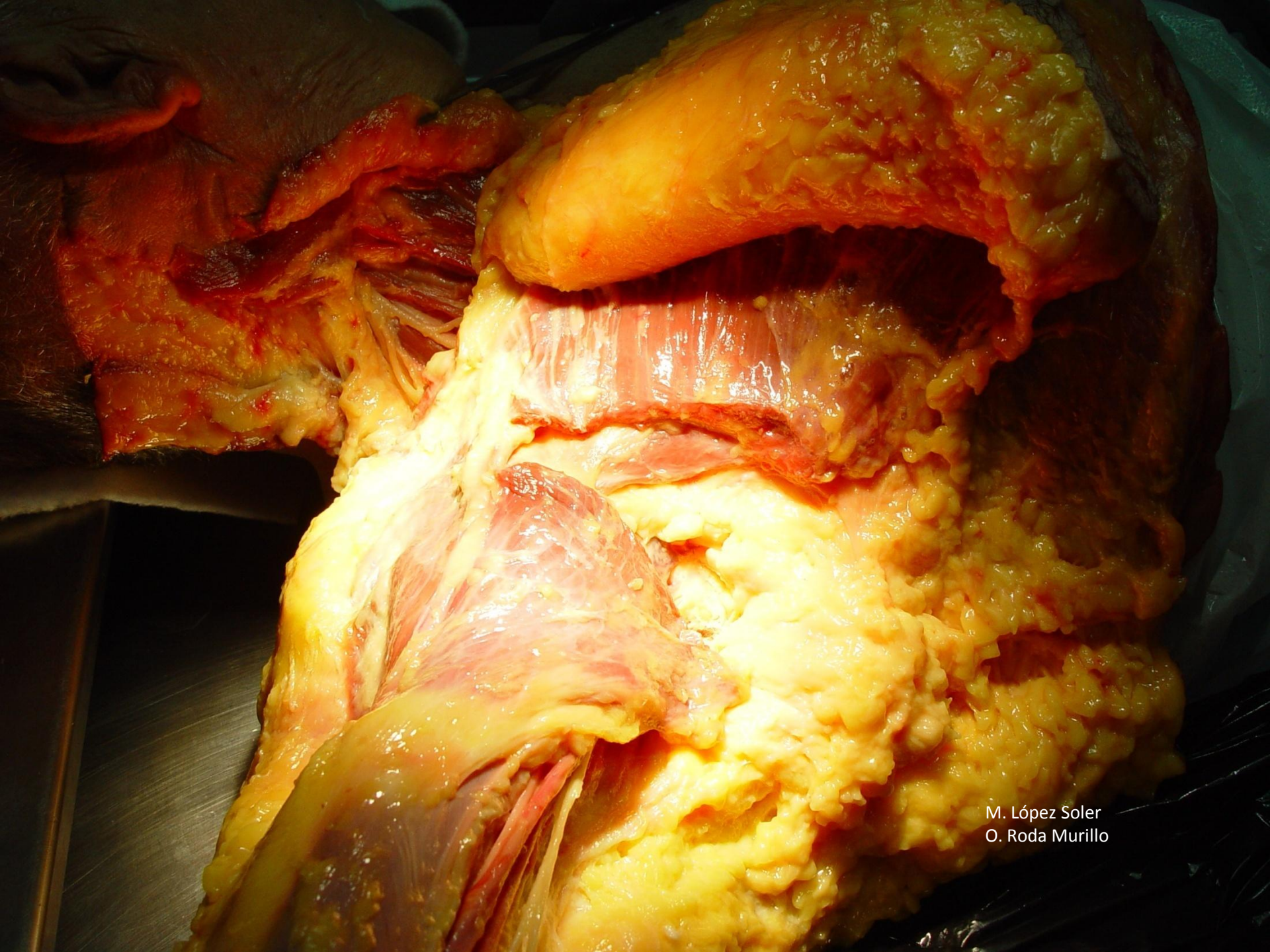
M. López Soler  
O. Roda Murillo



M. López Soler  
O. Roda Murillo


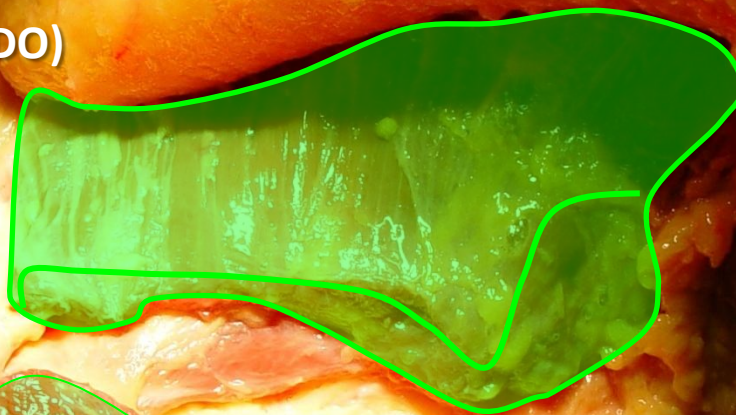


M. López Soler  
O. Roda Murillo

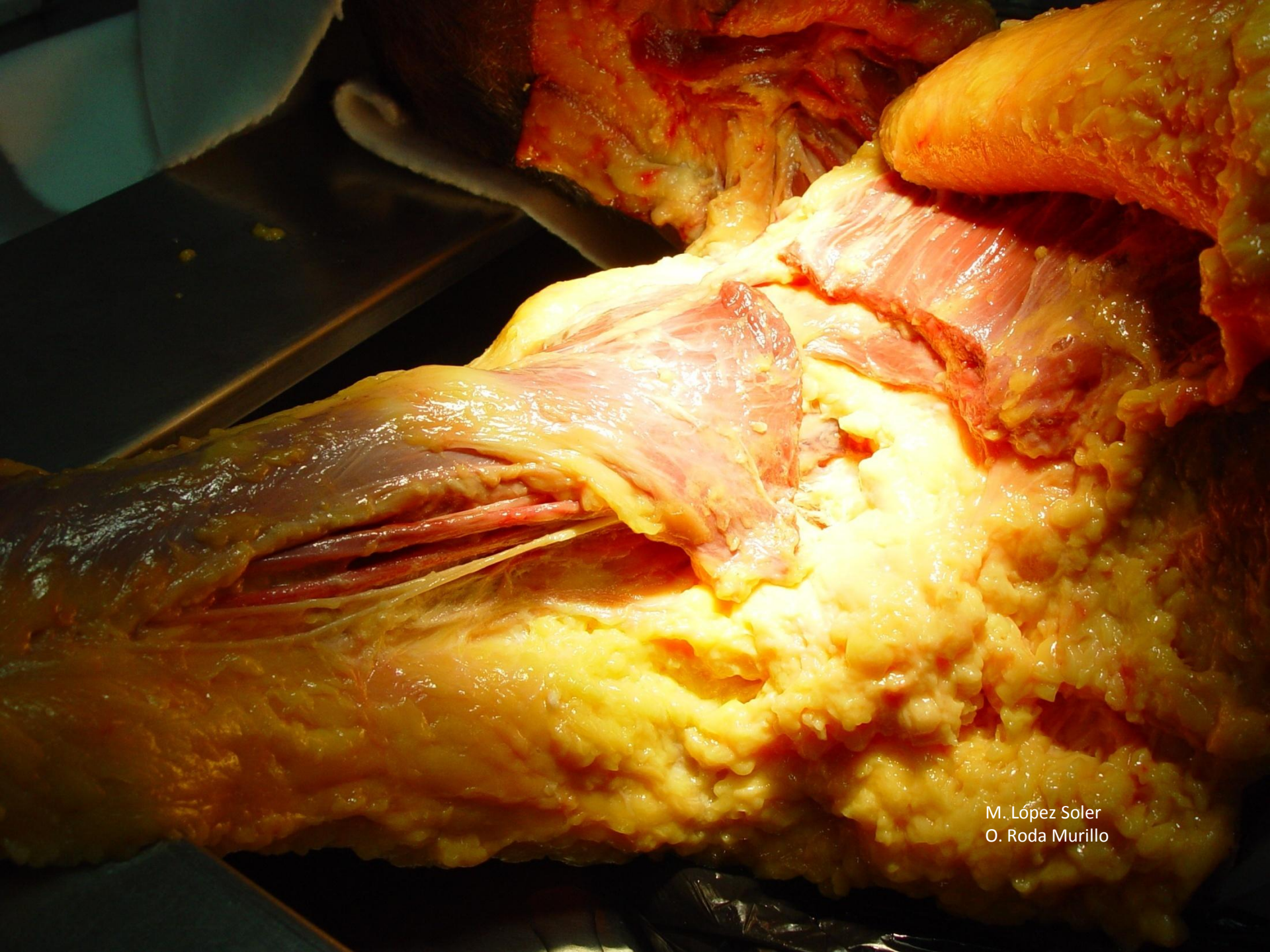


M. López Soler  
O. Roda Murillo

**MÚSCULO  
PECTORAL  
MAYOR  
(SECCIONADO)**



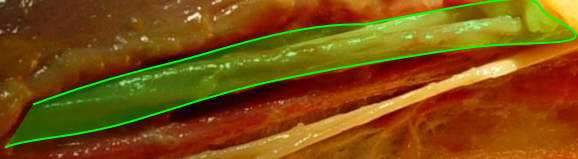
M. López Soler  
O. Roda Murillo



M. López Soler  
O. Roda Murillo

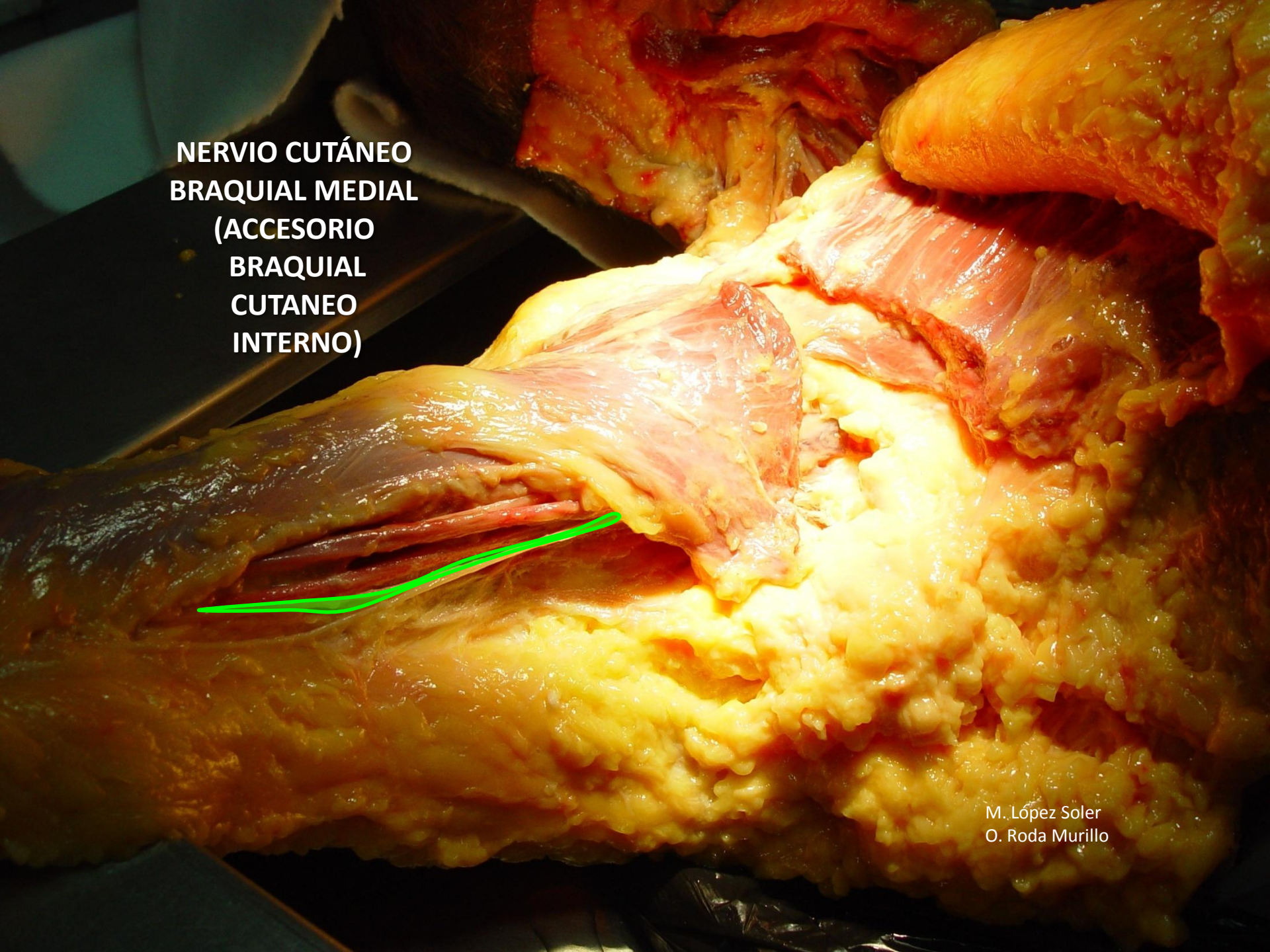


**ARTERIA  
AXILAR**



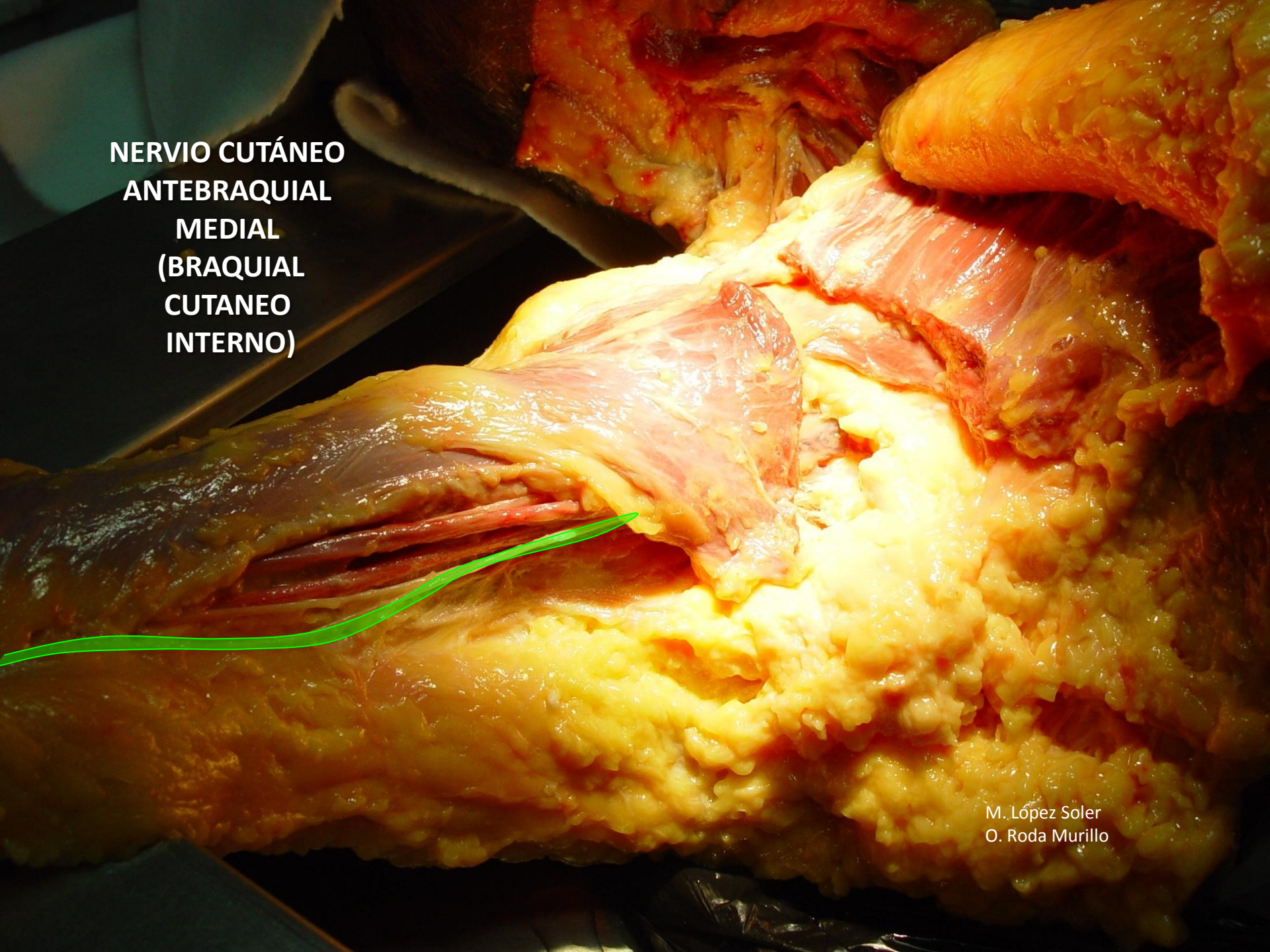
M. López Soler  
O. Roda Murillo

**NERVIO CUTÁNEO  
BRAQUIAL MEDIAL  
(ACCESORIO  
BRAQUIAL  
CUTANEO  
INTERNO)**

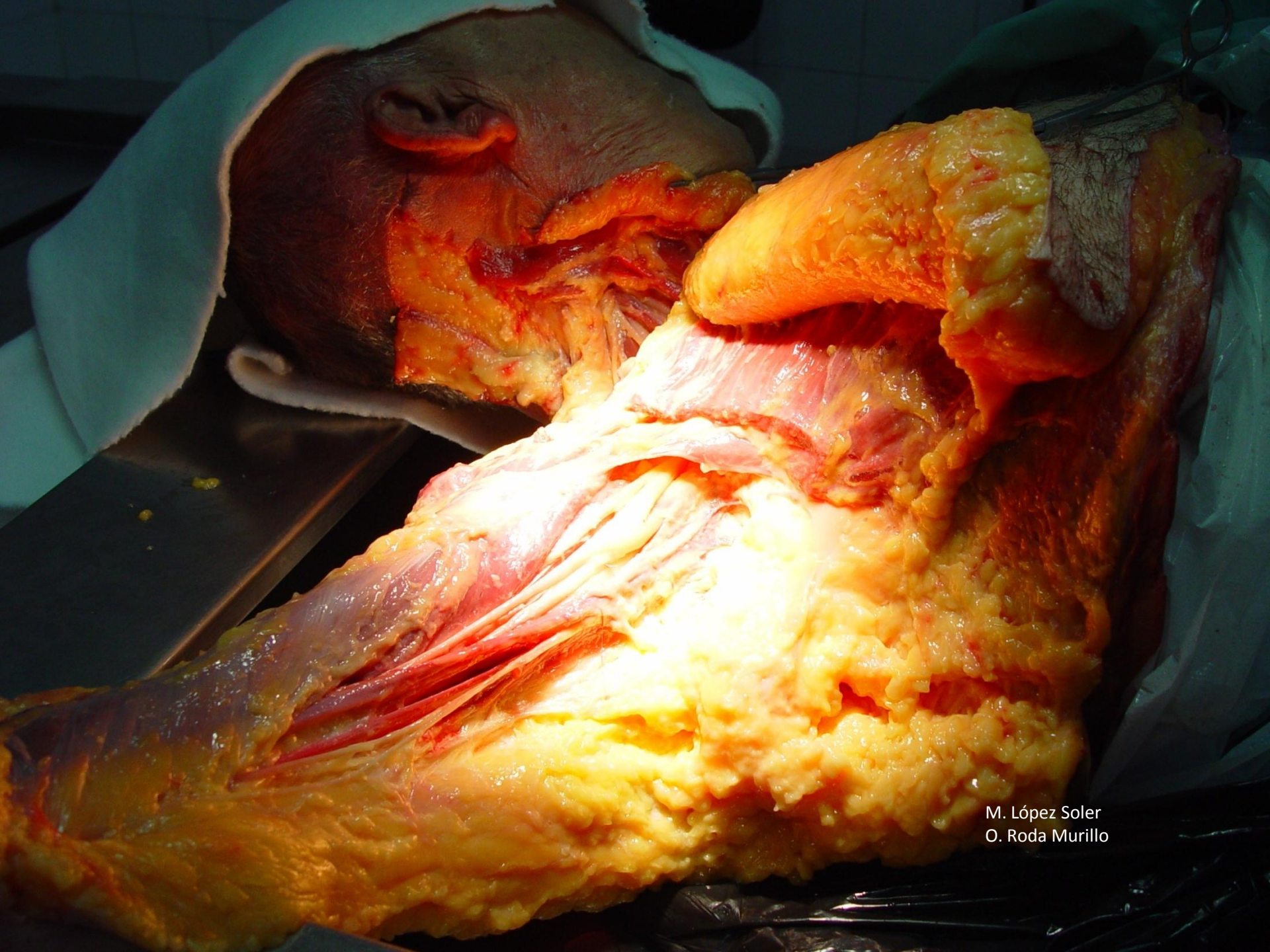


M. López Soler  
O. Roda Murillo

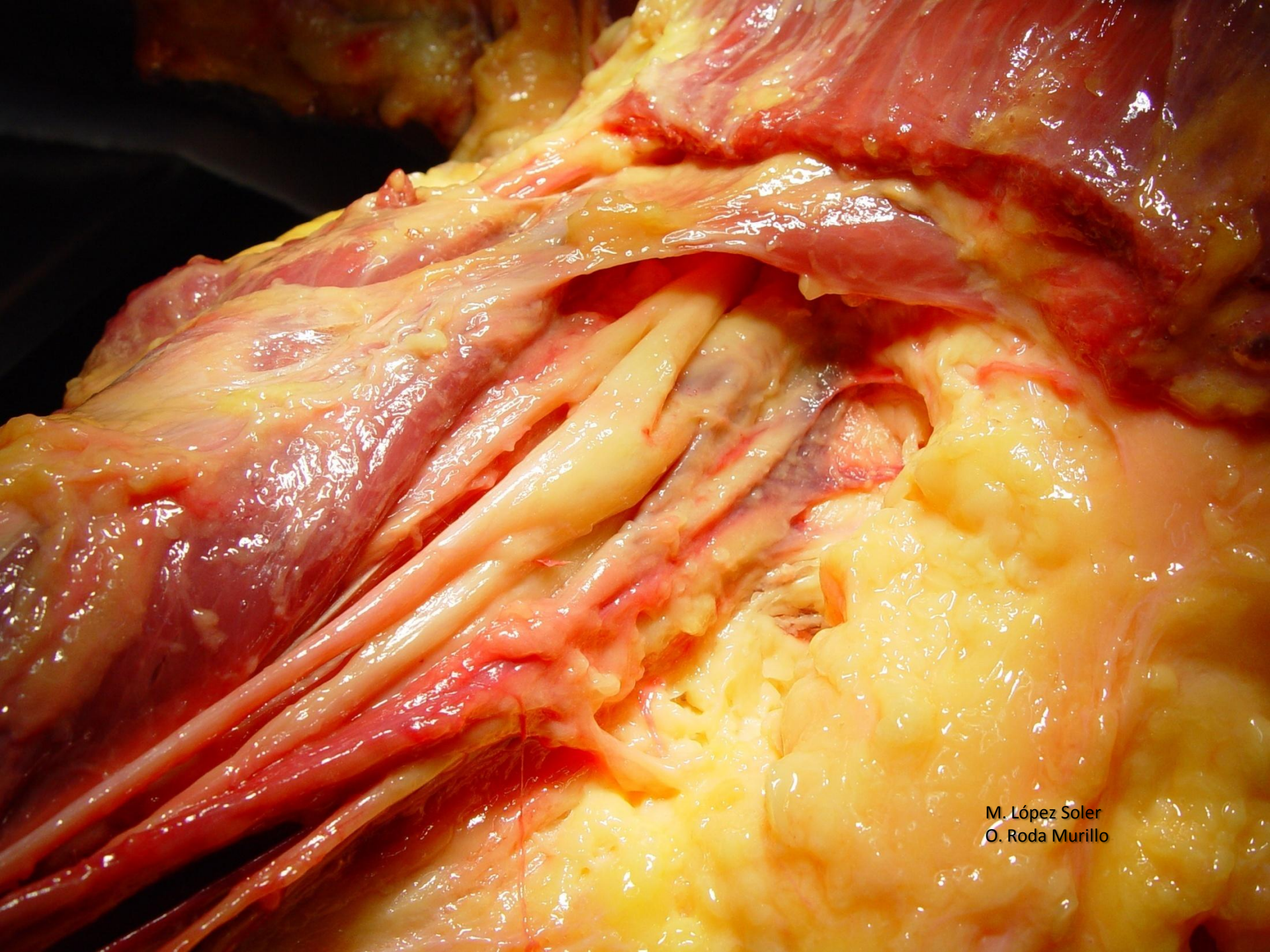
**NERVIO CUTÁNEO  
ANTEBRAQUIAL  
MEDIAL  
(BRAQUIAL  
CUTANEO  
INTERNO)**



M. López Soler  
O. Roda Murillo

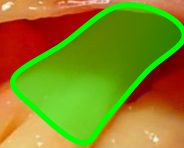

M. López Soler  
O. Roda Murillo

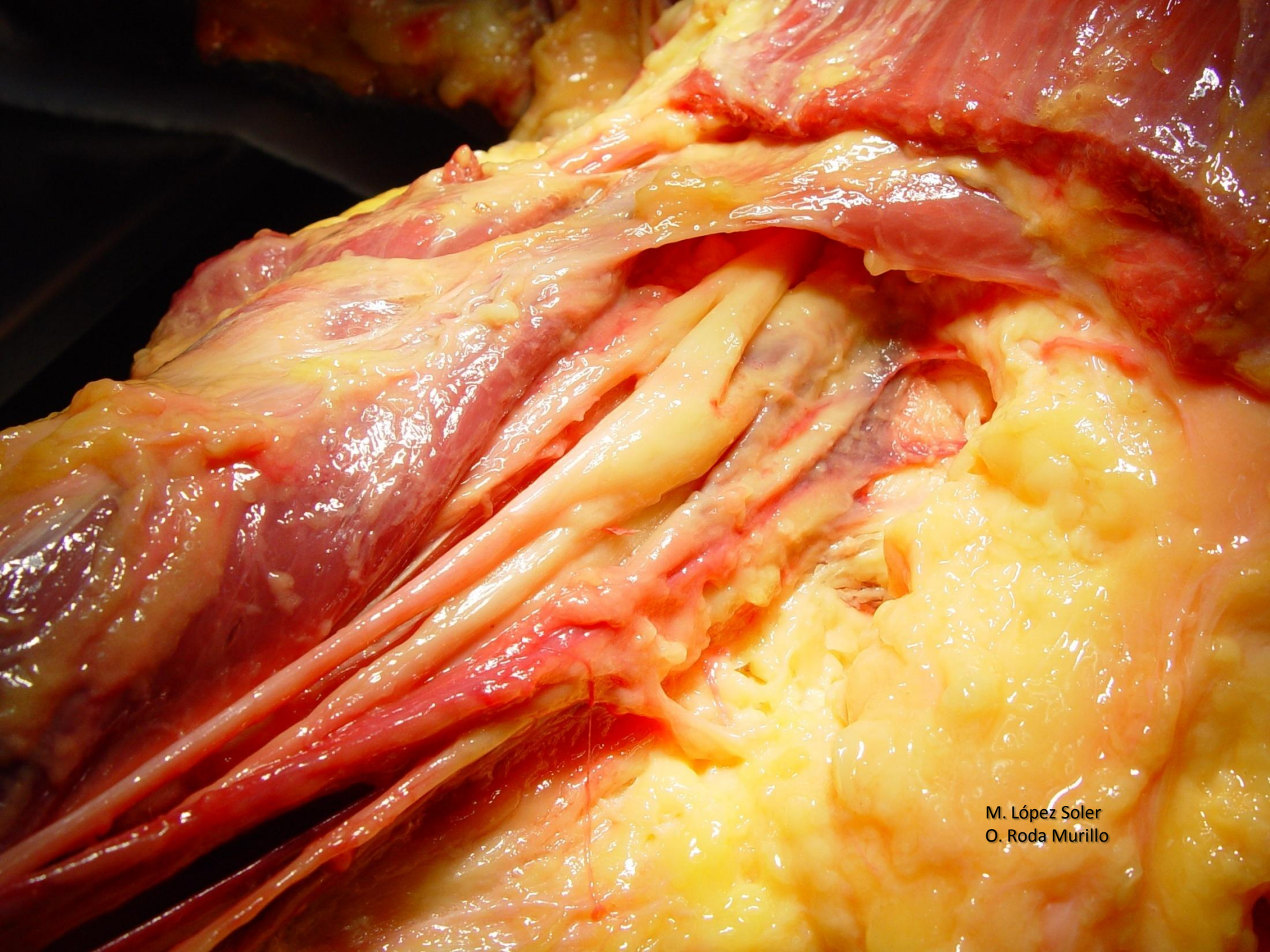

M. López Soler  
O. Roda Murillo

FÁSCICULO LATERAL

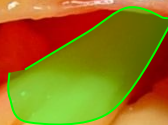


M. López Soler  
O. Roda Murillo



M. López Soler  
O. Roda Murillo

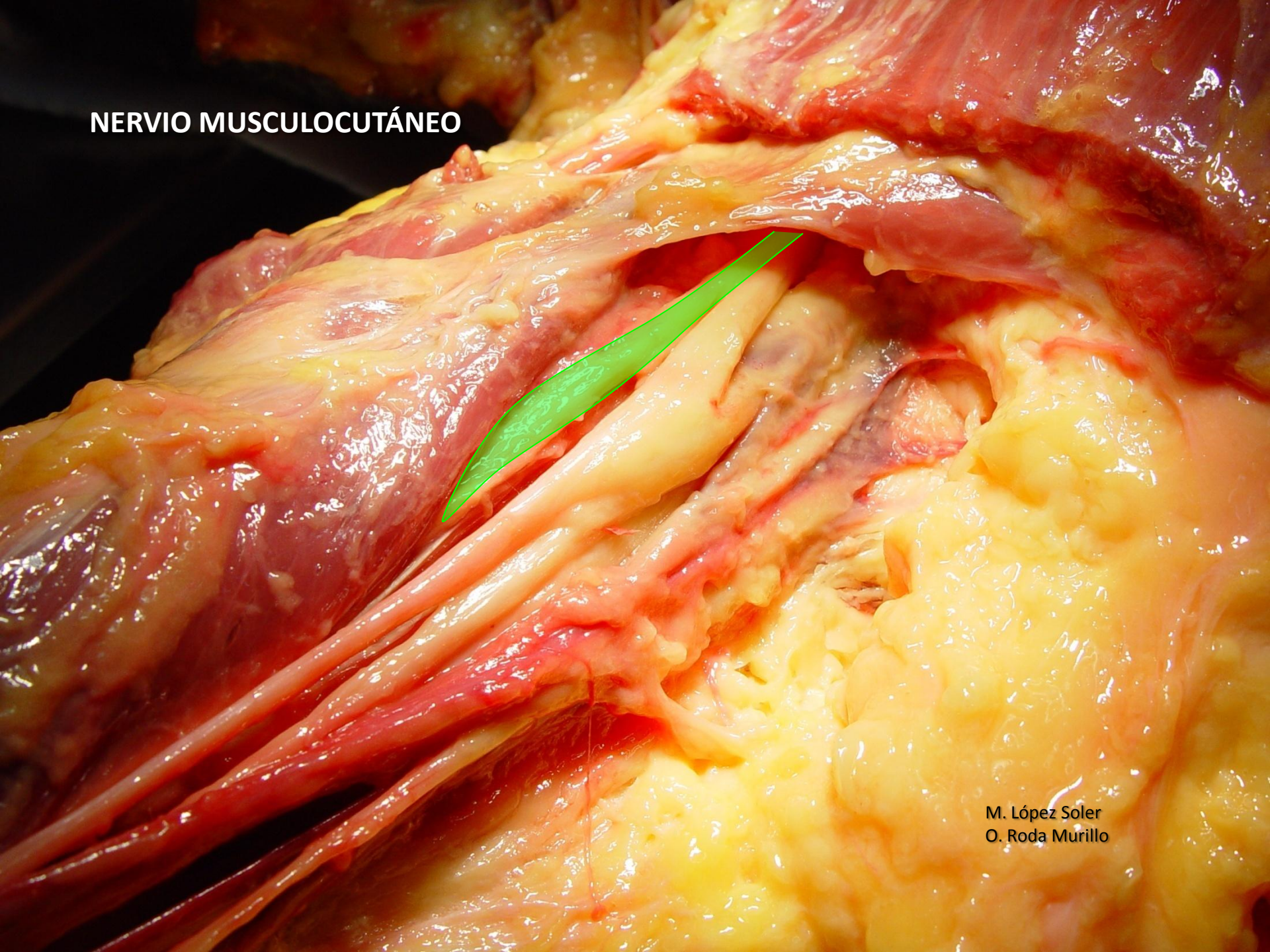
FÁSCICULO LATERAL



M. López Soler  
O. Roda Murillo



**NERVIO MUSCULOCUTÁNEO**



M. López Soler  
O. Roda Murillo

An anatomical dissection of a rat's forelimb, showing the median nerve highlighted in green. The nerve is seen running through the carpal tunnel, surrounded by yellow adipose tissue and red muscle fibers. The text 'NERVIO MEDIANO' is overlaid on the image.

**NERVIO MEDIANO**

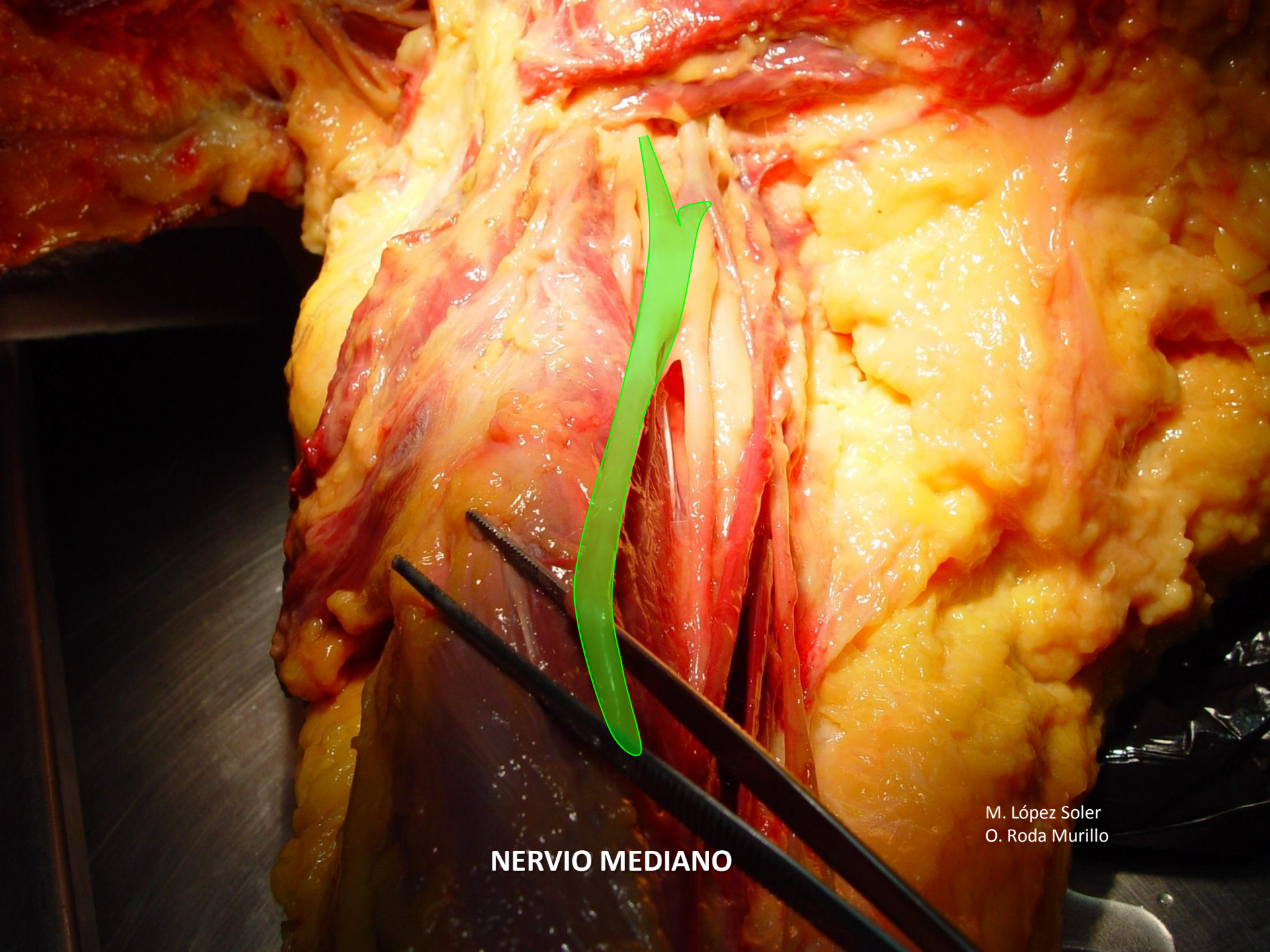
M. López Soler  
O. Roda Murillo



NERVIO CUBITAL

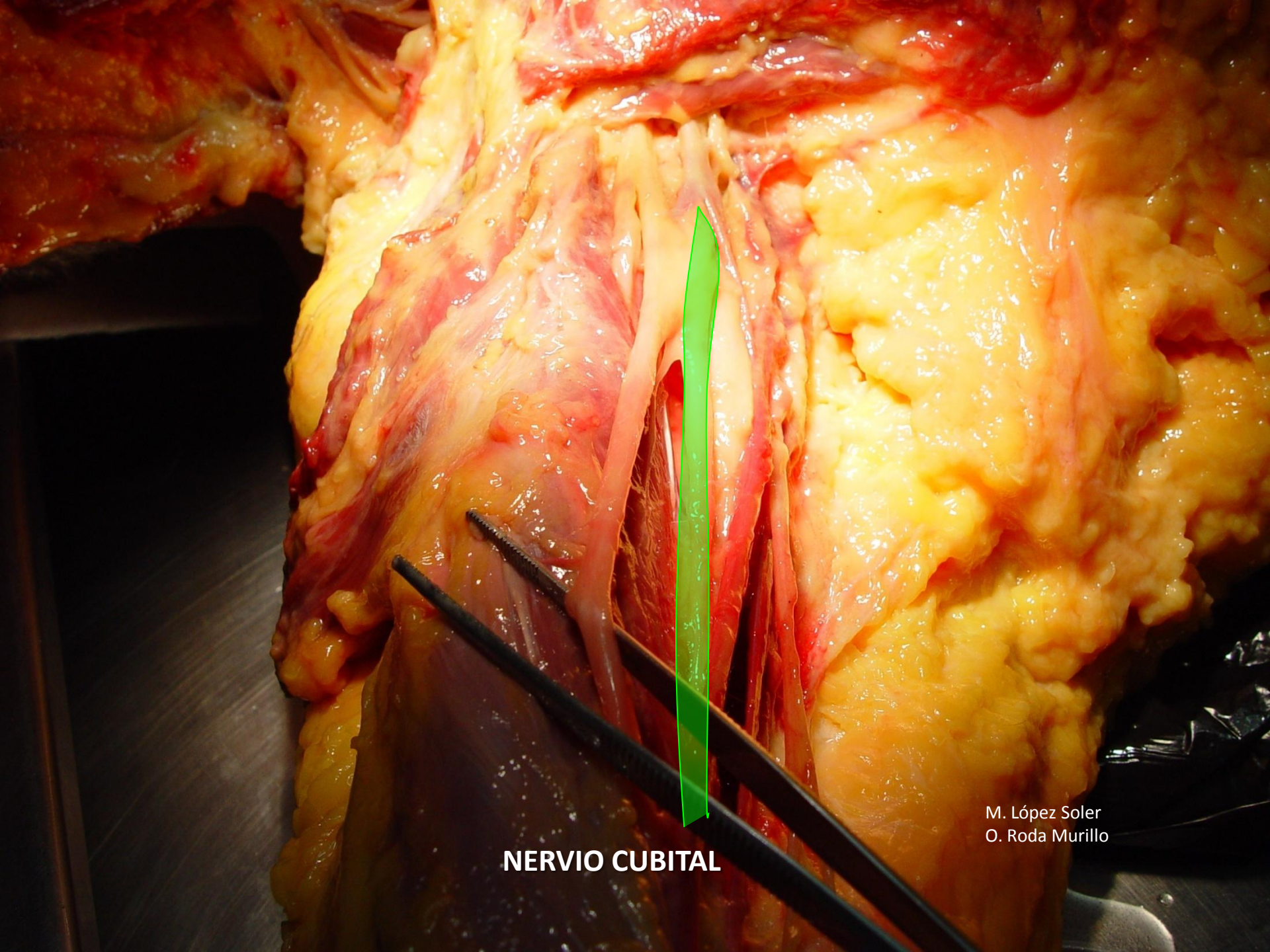
This is a detailed anatomical photograph of a human hand dissection. The focus is on the ulnar nerve, which is highlighted with a bright green outline. The nerve is shown running along the length of the ulna bone. Surrounding the nerve and bone are various muscles, tendons, and connective tissues, all appearing moist and pinkish-red. The background is dark, making the anatomical structures stand out. The text 'NERVIO CUBITAL' is printed in white capital letters to the left of the nerve. In the bottom right corner, the names of the individuals who prepared the dissection are listed.

M. López Soler  
O. Roda Murillo



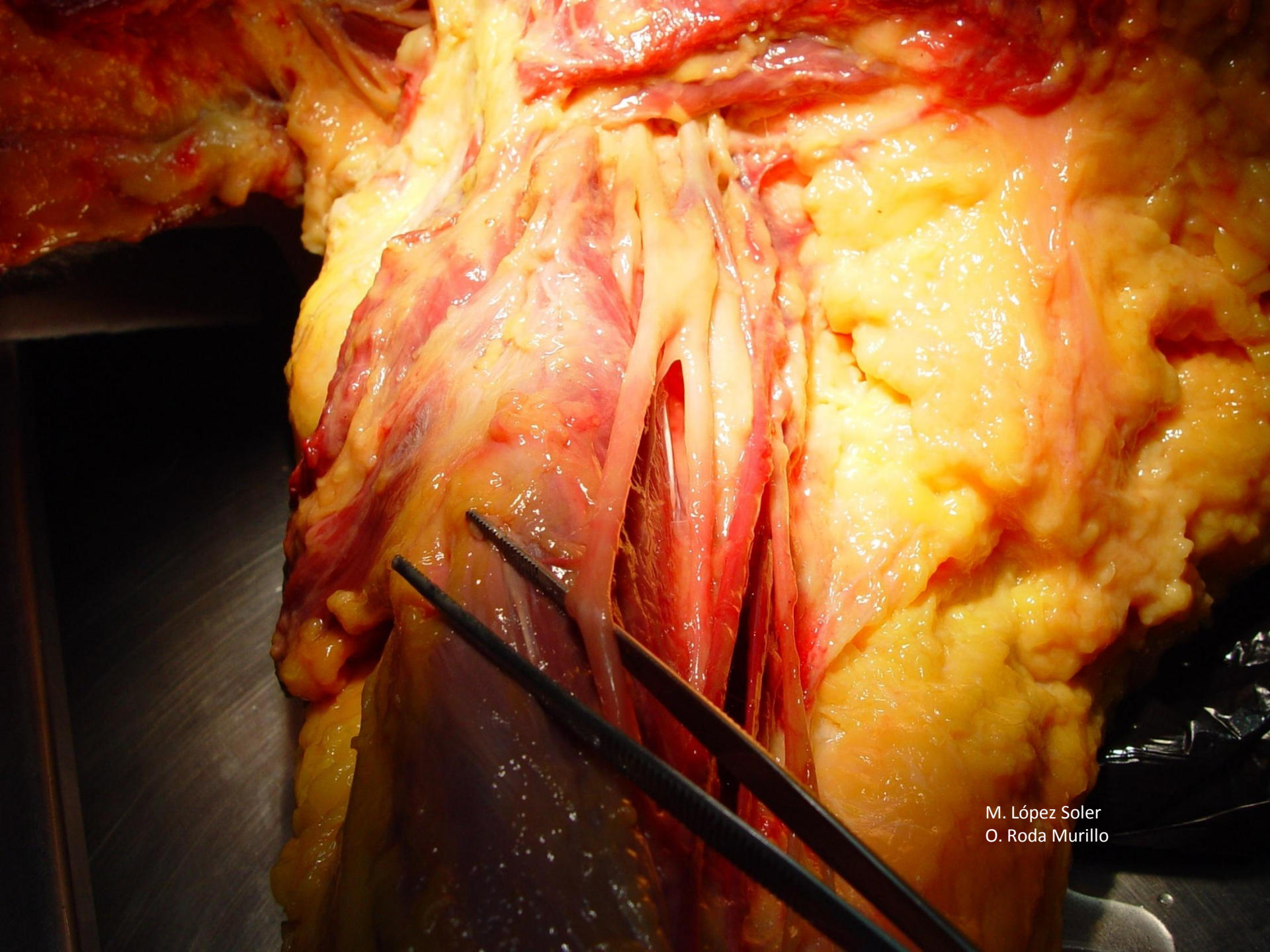
**NERVIO MEDIANO**

M. López Soler  
O. Roda Murillo

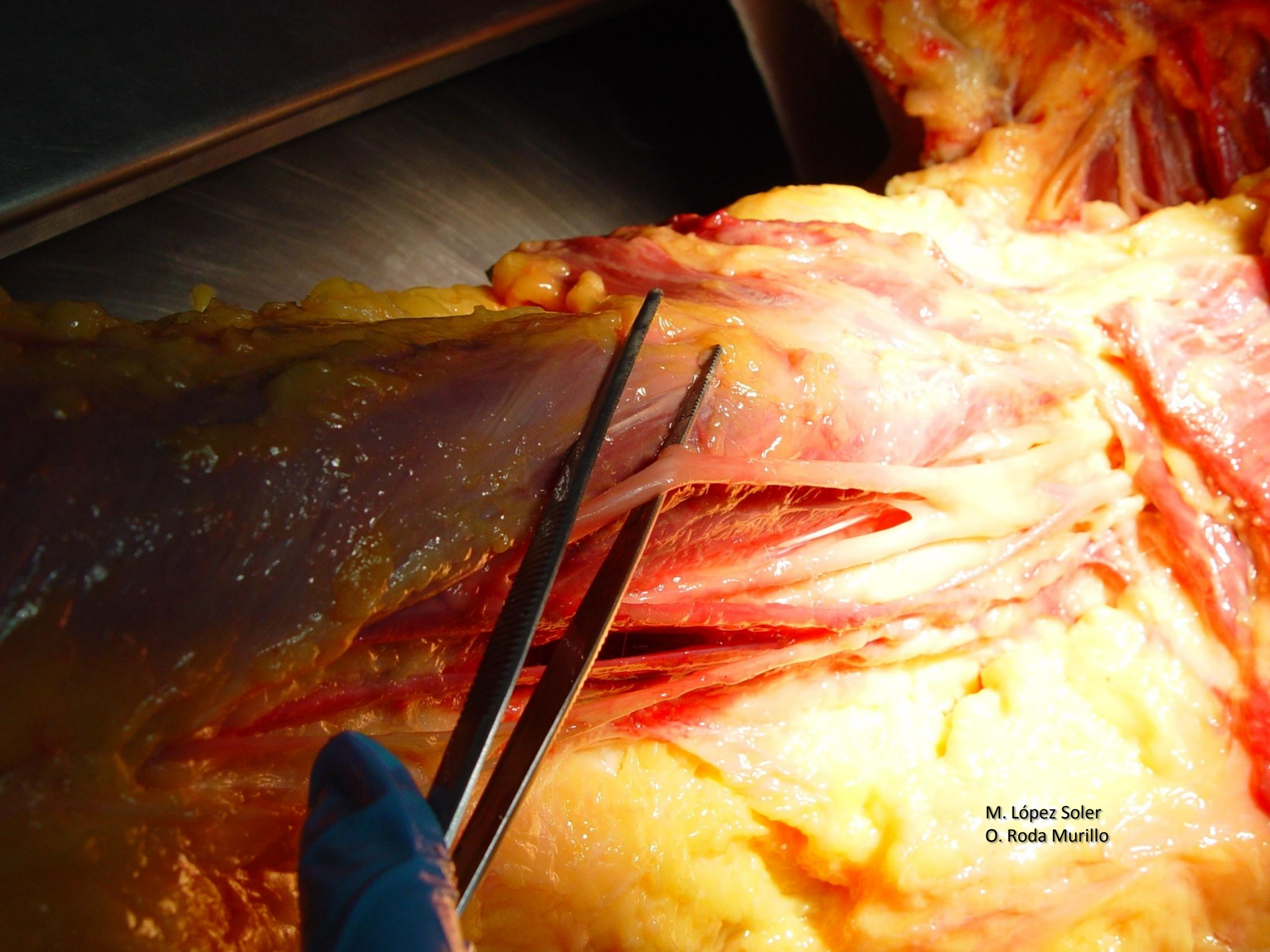


**NERVIO CUBITAL**

M. López Soler  
O. Roda Murillo

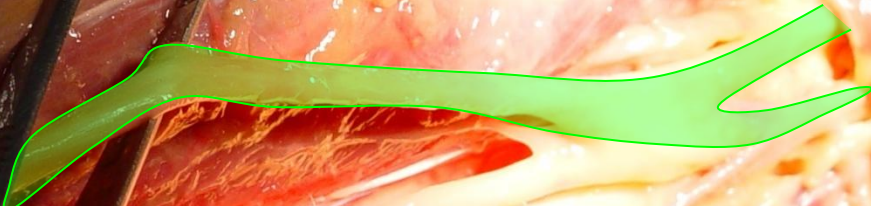


M. López Soler  
O. Roda Murillo



M. López Soler  
O. Roda Murillo

**NERVIO MEDIANO**



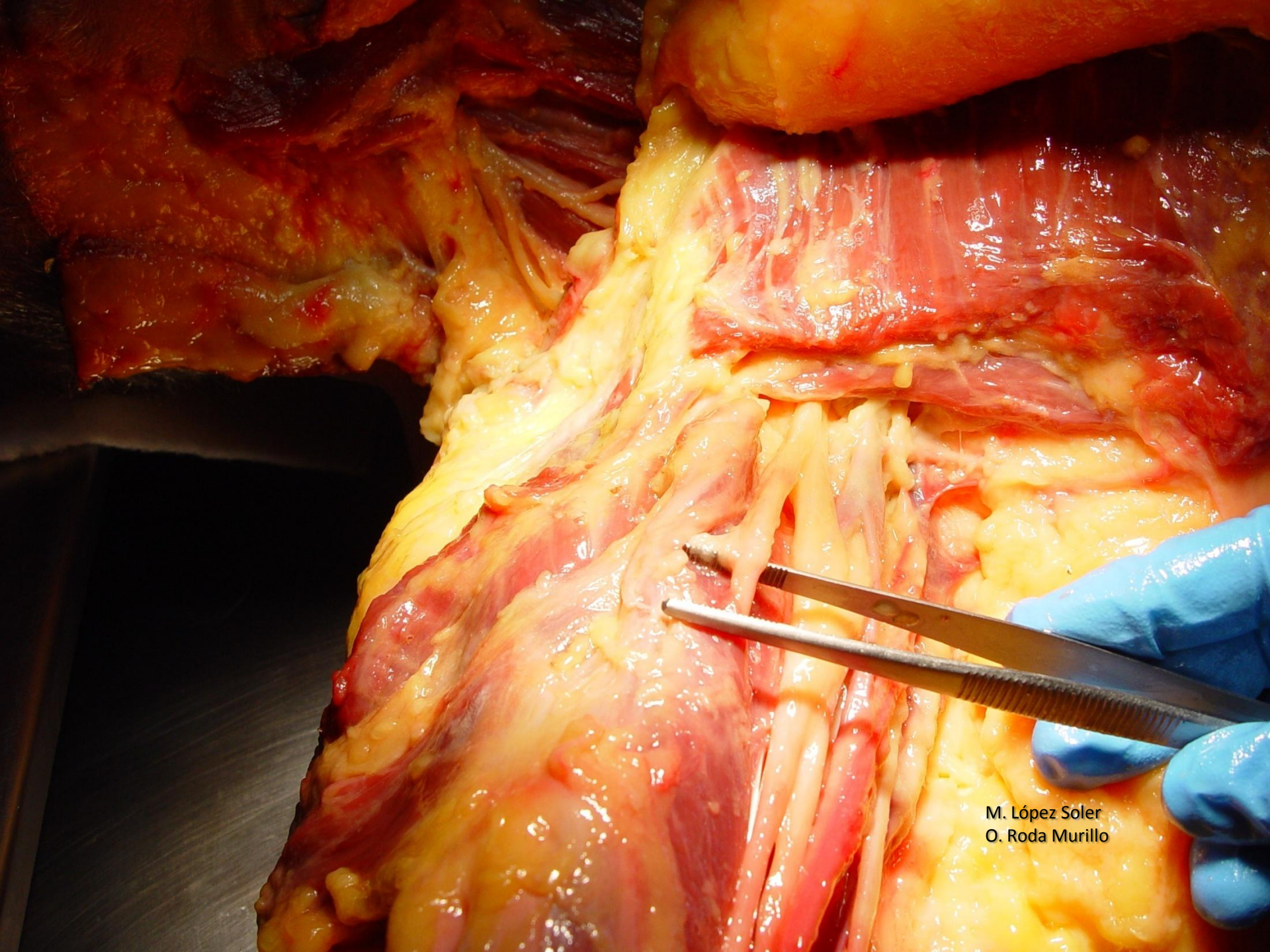
M. López Soler  
O. Roda Murillo



An anatomical dissection of a cadaveric specimen showing the cubital nerve. The nerve is a pale, cord-like structure running horizontally across the middle of the image. It is held in place by a pair of black surgical forceps. The surrounding tissue is a mix of pinkish-red muscle and yellowish adipose tissue. A green line is drawn along the length of the nerve to highlight it. The text 'NERVIO CUBITAL' is printed in white on the left side of the image. In the bottom right corner, the names 'M. López Soler' and 'O. Roda Murillo' are printed in black.

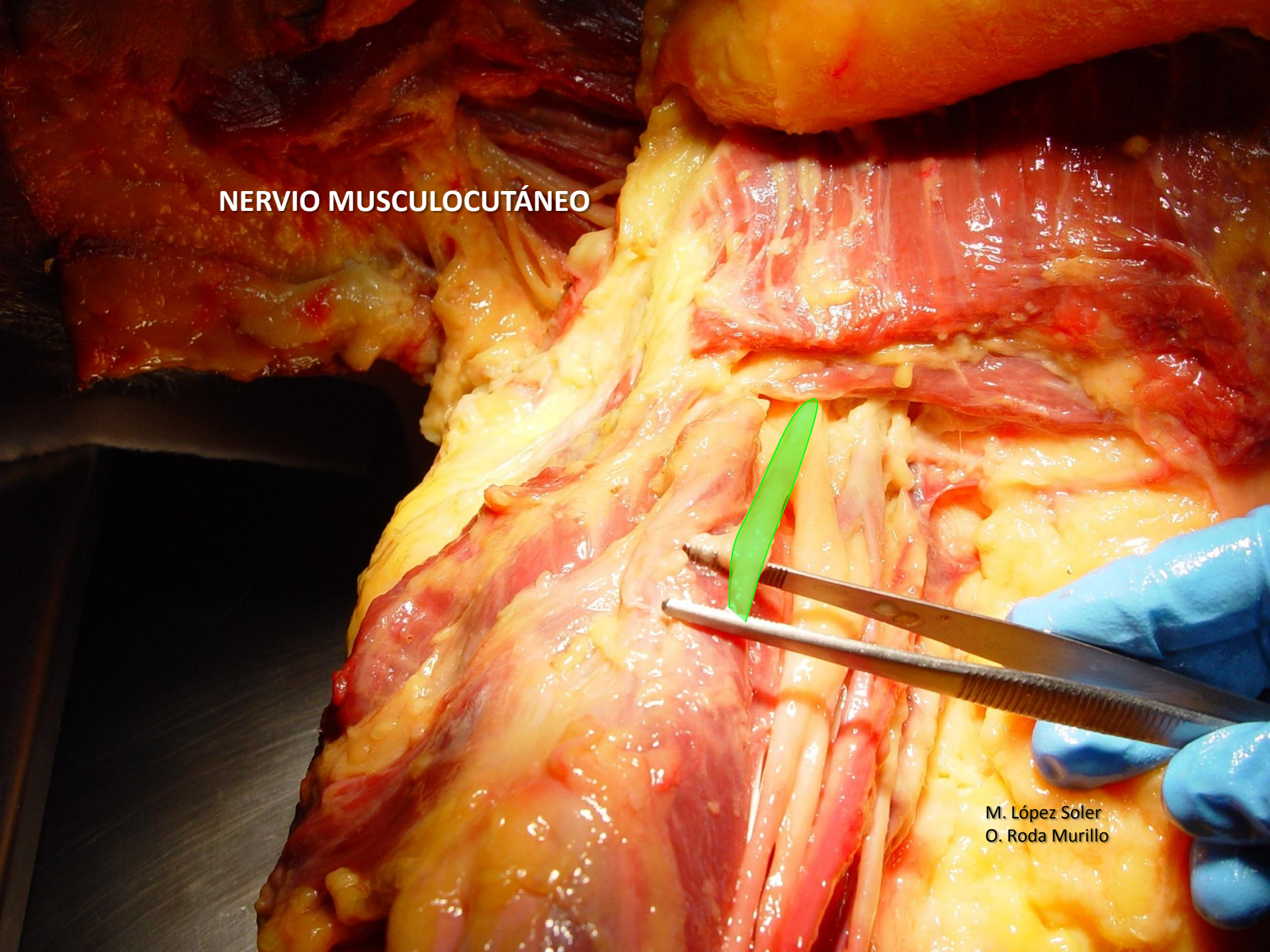
**NERVIO CUBITAL**

M. López Soler  
O. Roda Murillo

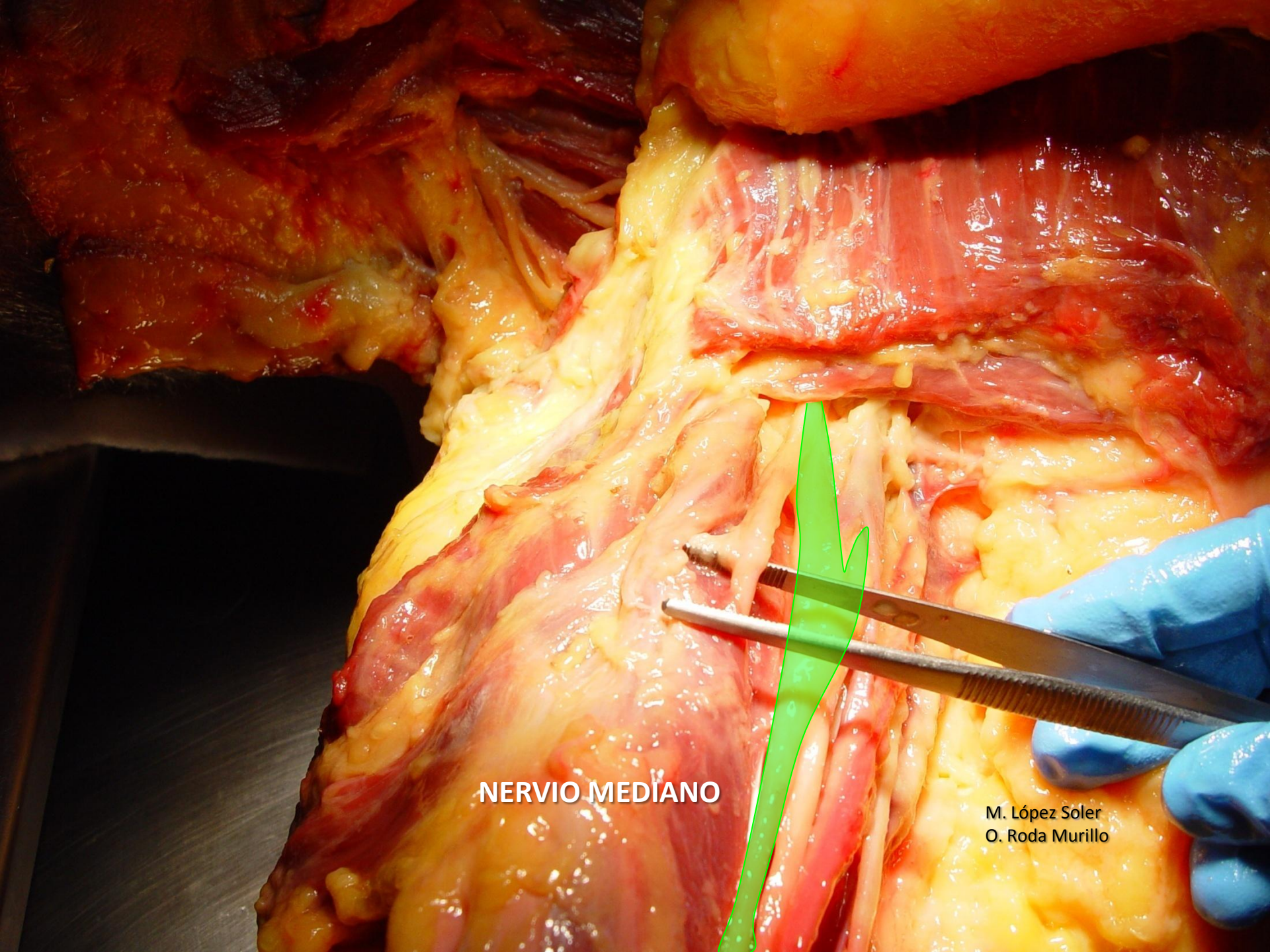


M. López Soler  
O. Roda Murillo

# NERVIO MUSCULOCUTÁNEO

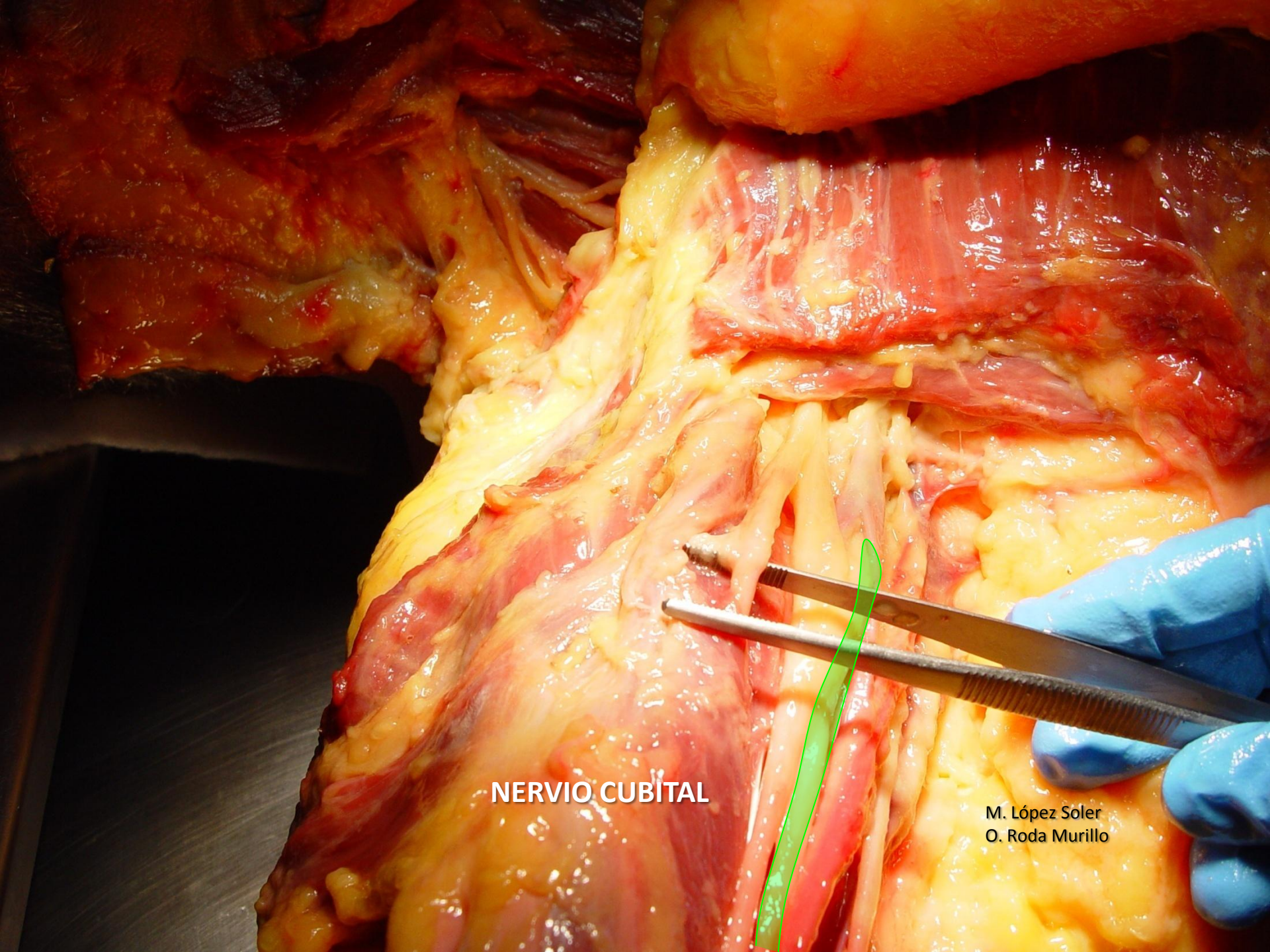


M. López Soler  
O. Roda Murillo



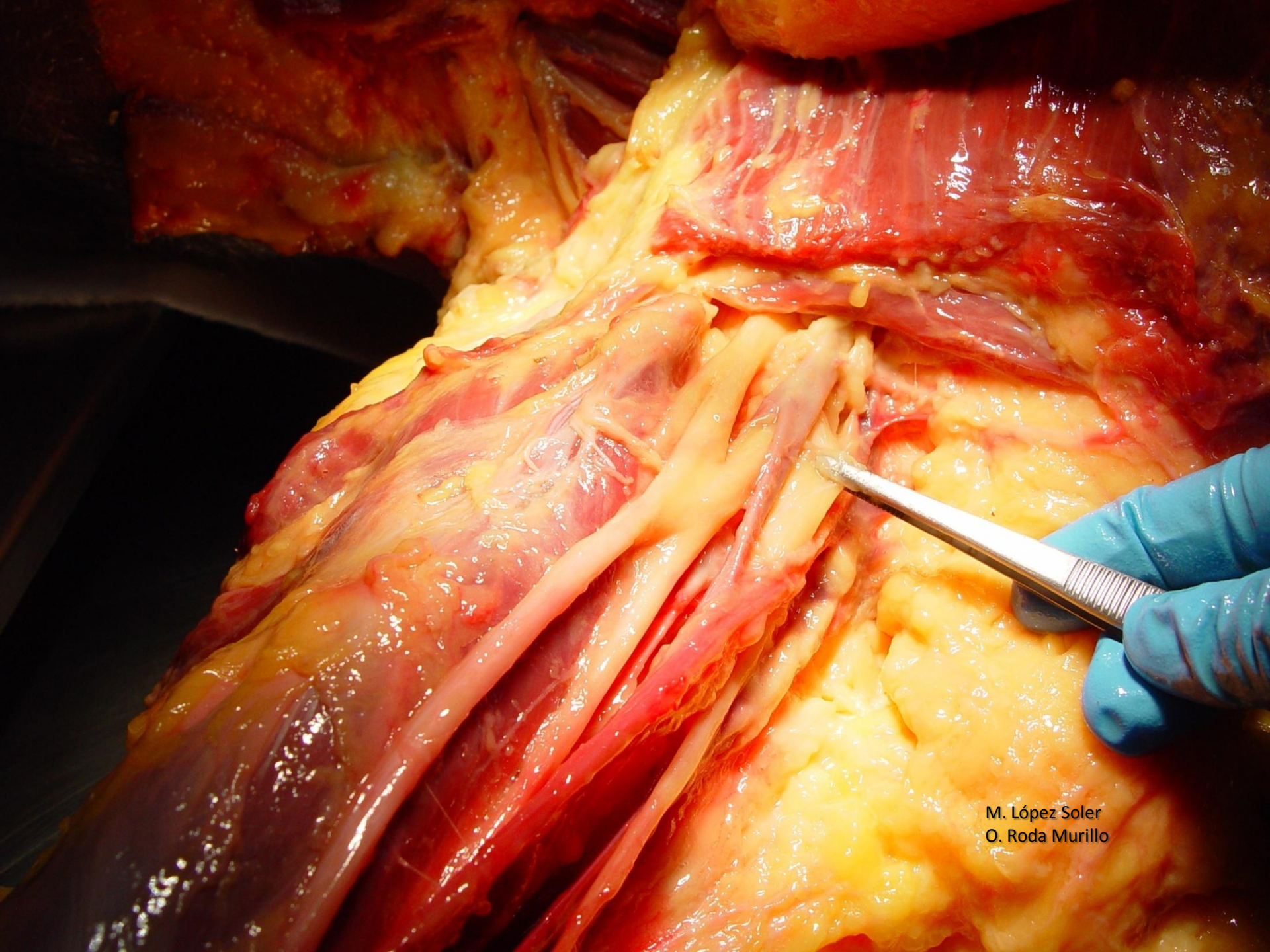
**NERVIO MEDIANO**

M. López Soler  
O. Roda Murillo



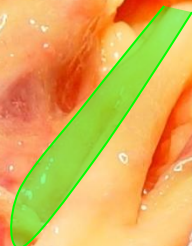
**NERVIO CUBITAL**

M. López Soler  
O. Roda Murillo



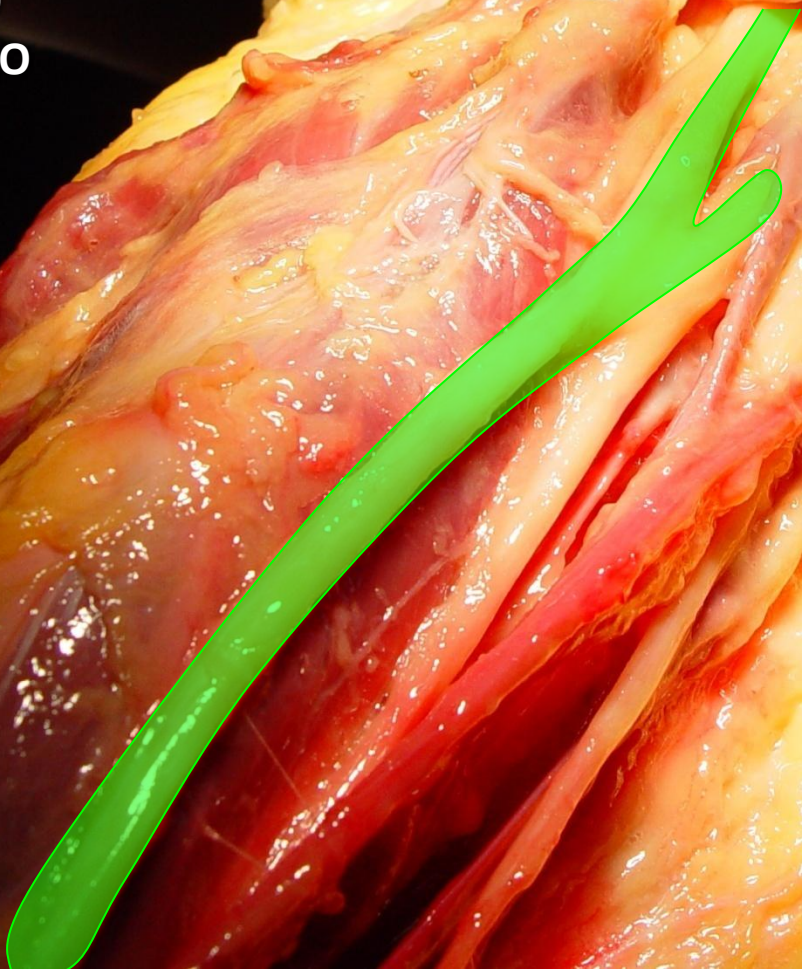M. López Soler  
O. Roda Murillo

**NERVIO  
MUSCULOCUTÁNEO**



M. López Soler  
O. Roda Murillo

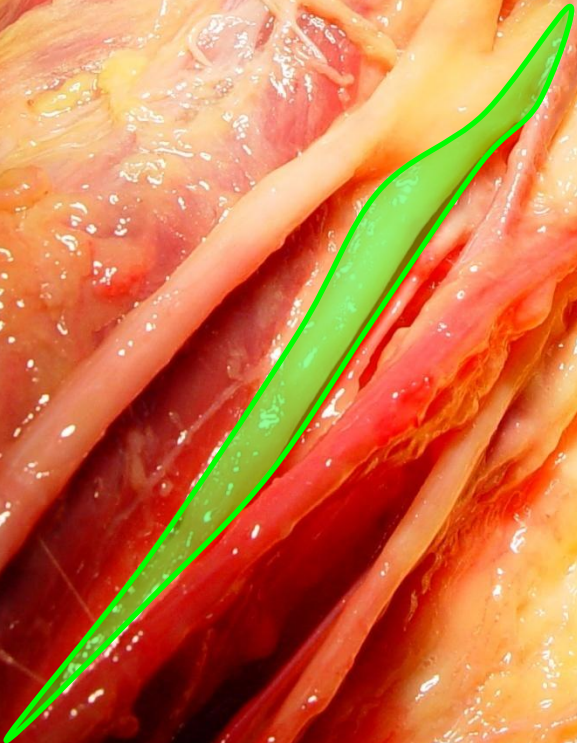**NERVIO  
MEDIANO**



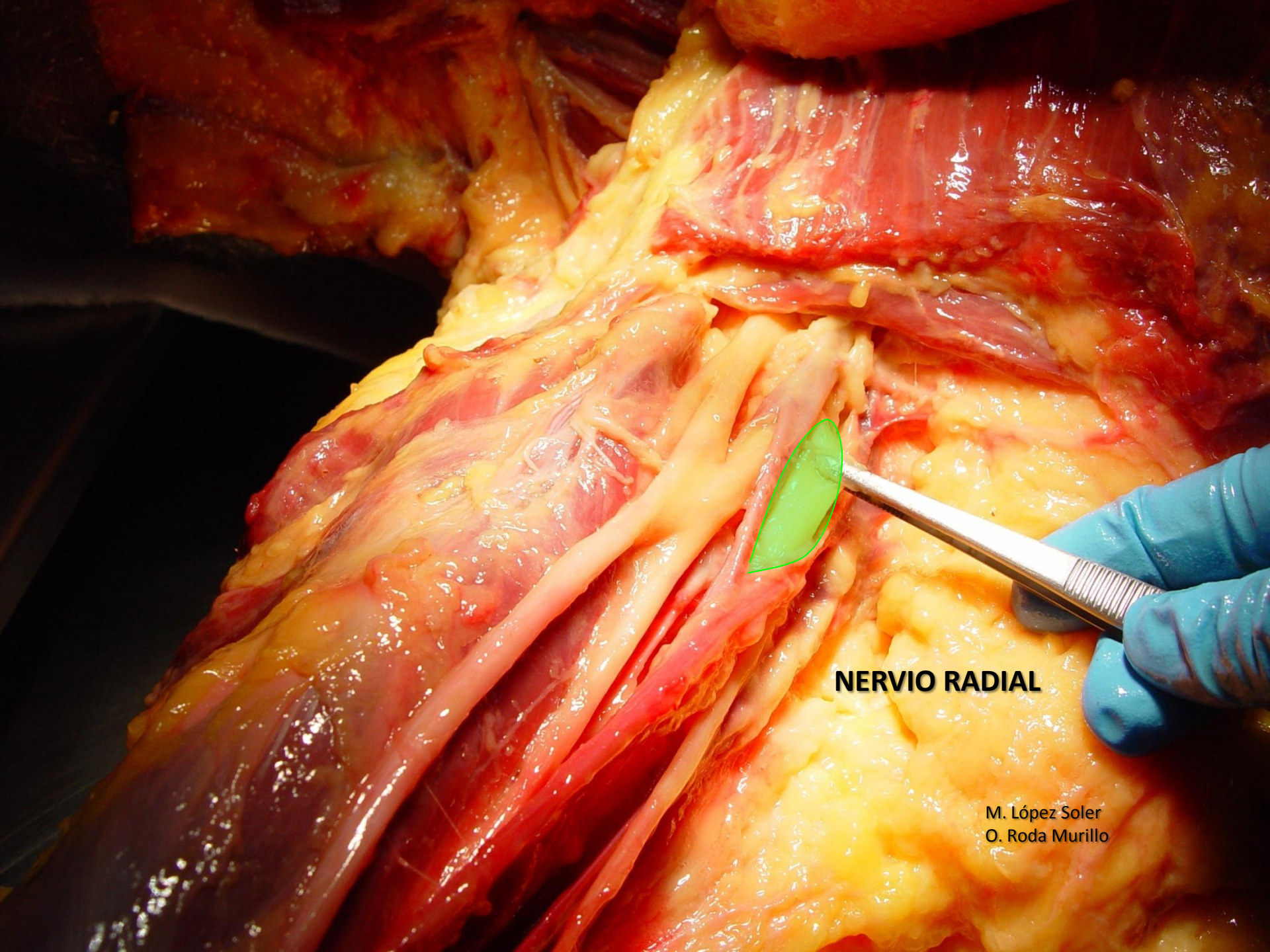
M. López Soler  
O. Roda Murillo



**NERVIO  
CUBITAL**

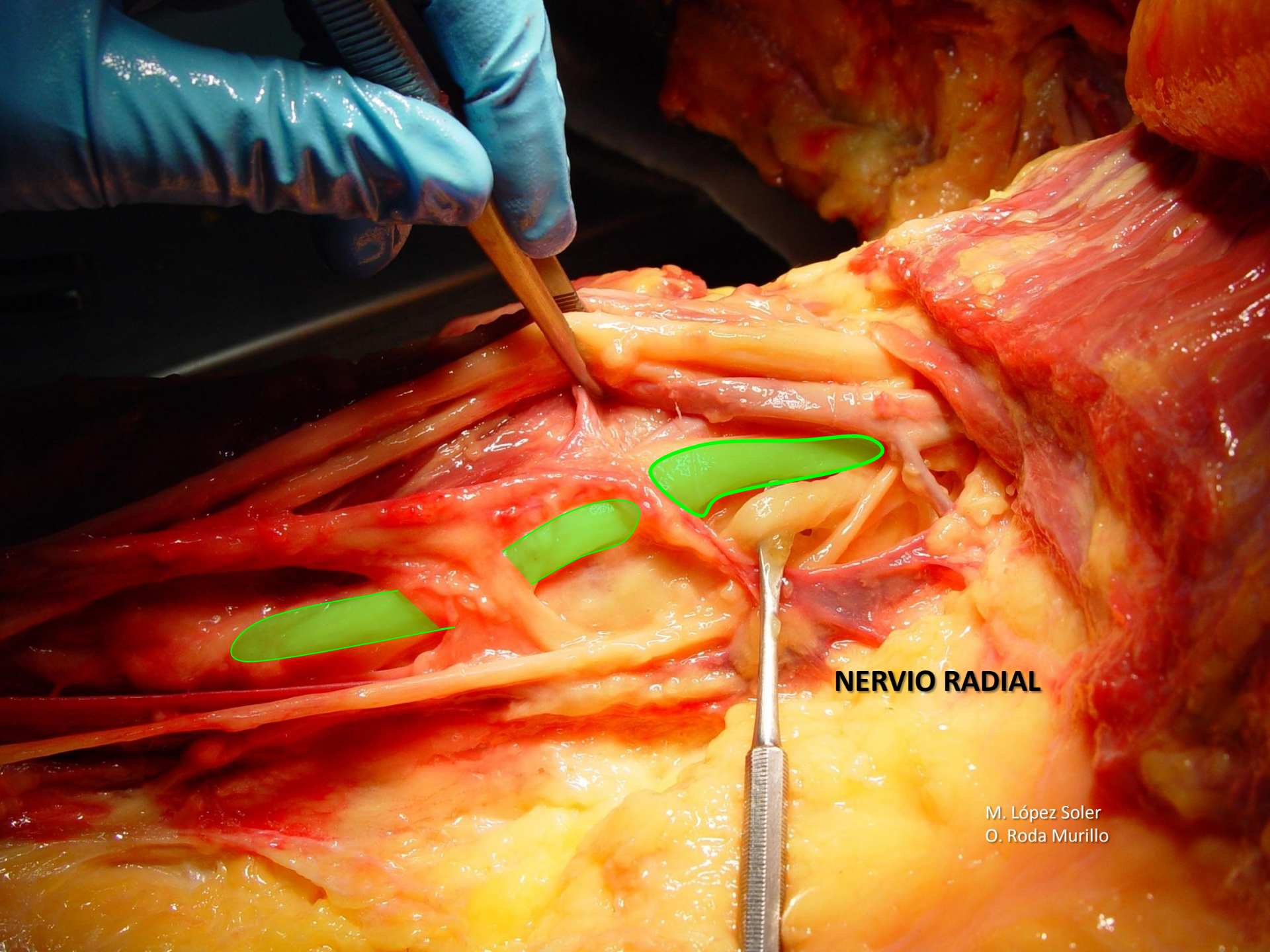


M. López Soler  
O. Roda Murillo



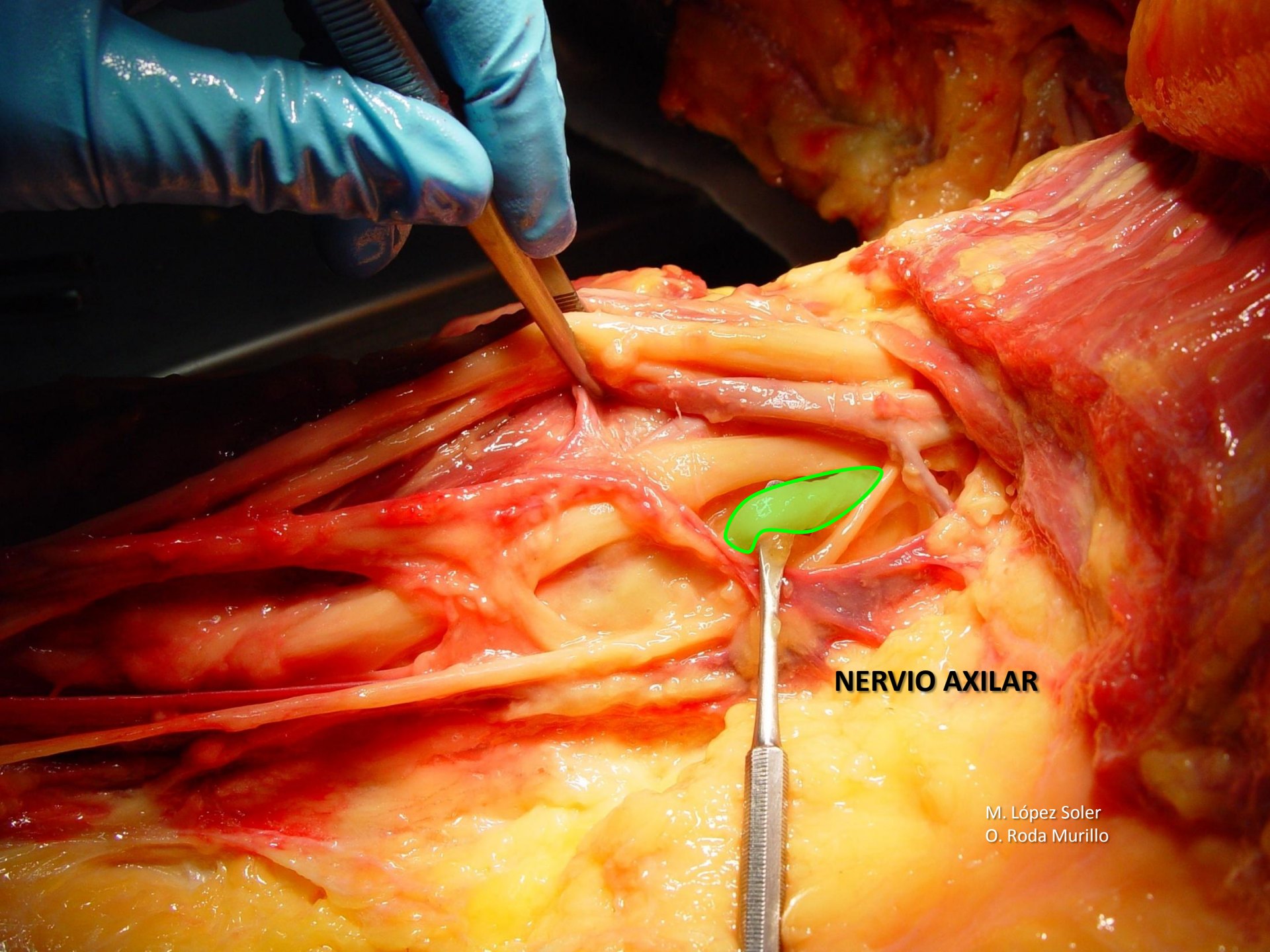
**NERVIO RADIAL**

M. López Soler  
O. Roda Murillo



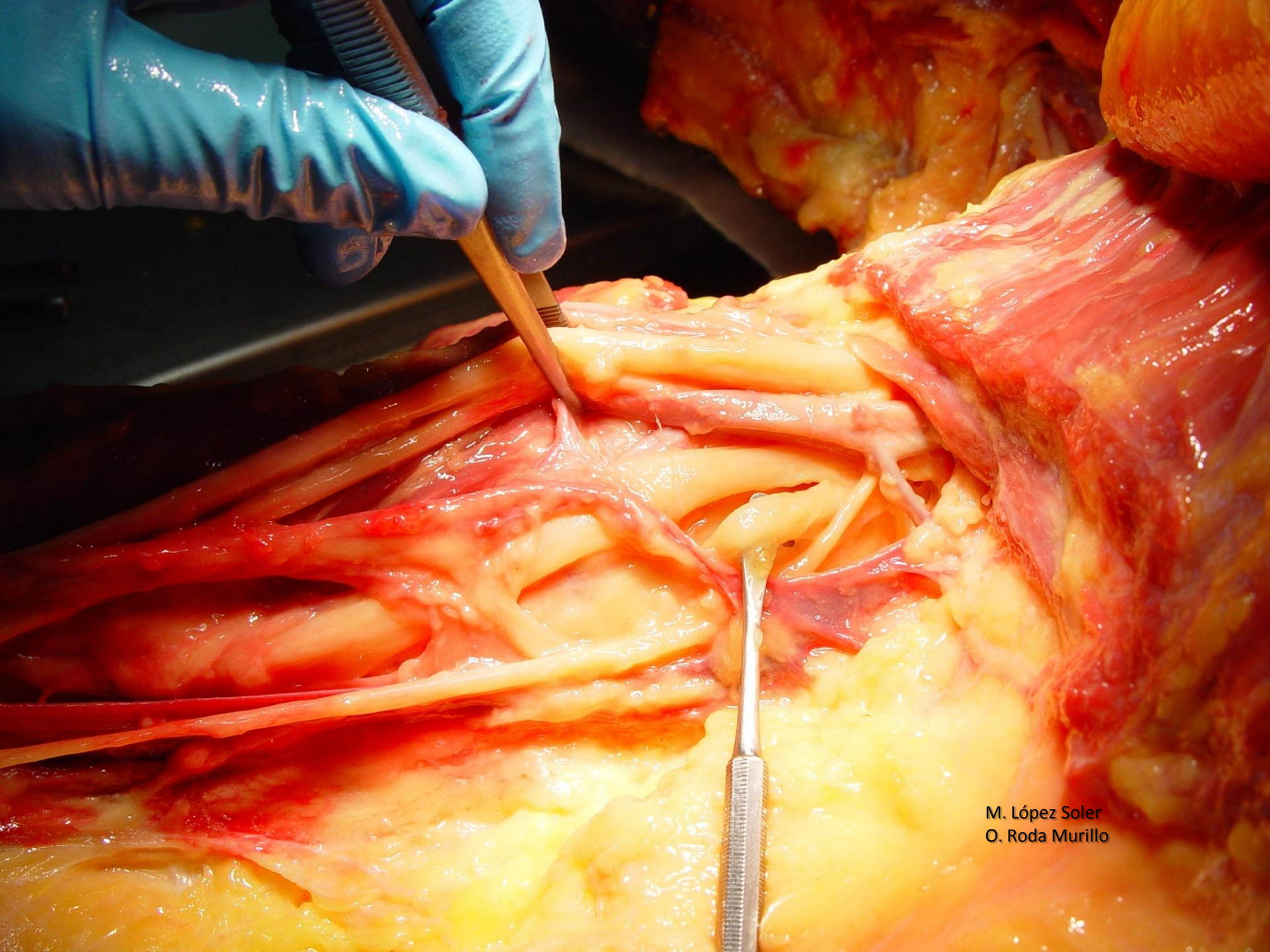
**NERVIO RADIAL**

M. López Soler  
O. Roda Murillo

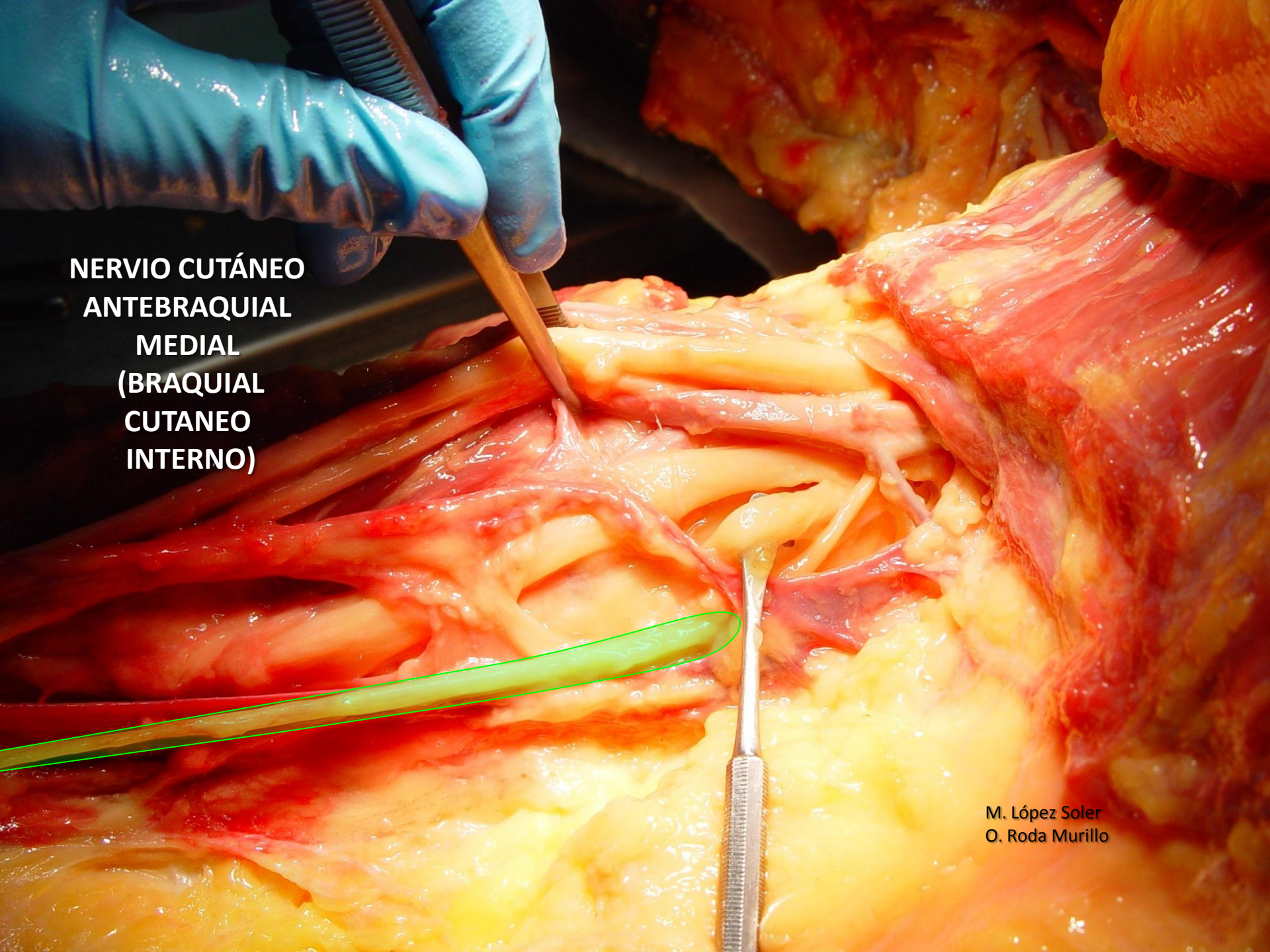


**NERVIO AXILAR**

M. López Soler  
O. Roda Murillo

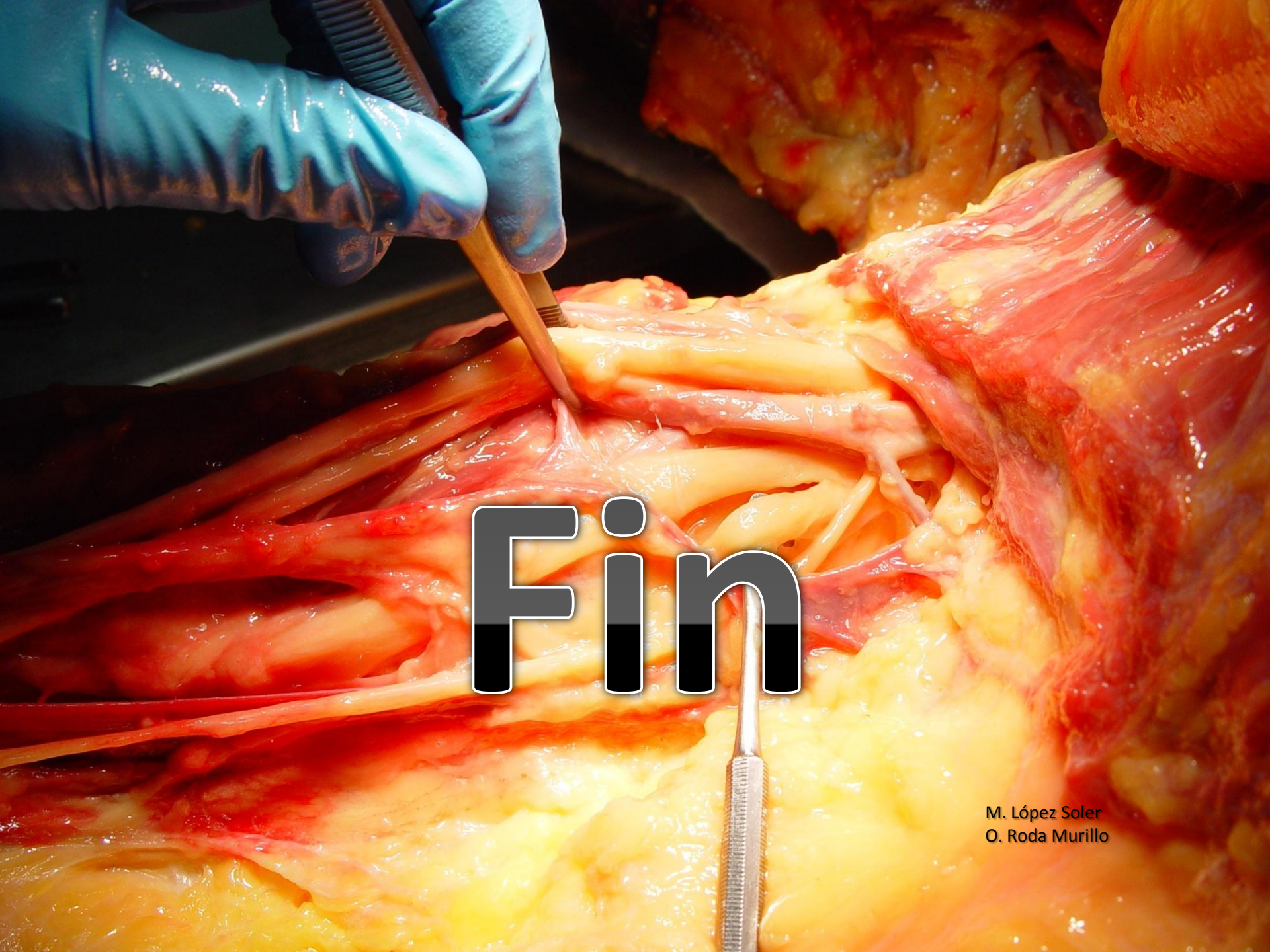


M. López Soler  
O. Roda Murillo

An anatomical dissection of the medial brachial cutaneous nerve. The nerve is shown as a long, pale, cylindrical structure, highlighted with a green oval. It is surrounded by yellow adipose tissue and red muscle fibers. Surgical instruments, including a pair of blue gloves and a metal retractor, are visible, indicating an operative or dissection setting. The nerve is being held and examined by the gloved hand.

**NERVIO CUTÁNEO  
ANTEBRAQUIAL  
MEDIAL  
(BRAQUIAL  
CUTANEO  
INTERNO)**

M. López Soler  
O. Roda Murillo



**Fin**

M. López Soler  
O. Roda Murillo